

# KARPAGAM ACADEMY OF HIGHER EDUCATION

CLASS: II M.Sc MB	COURSE NAME: MEDICAL MYCOLOGY AND PARASITOLOGY
COURSE CODE: 18MBP303	SYLLABUS BATCH-2018-2020
M.Sc. Microbiology	2018-2019
18MBP303	MEDICAL MYCOLOGY AND PARASITOLOGY Semester - III 4H –4C

**Instruction Hours / Week: L: 4 T: 0 P: 0**

**Marks: Internal: 40 External: 60 Total: 100**

**End Semester Exam: 3 Hours**

## COURSE OBJECTIVES

Should be familiar with current developments and advances in the field of Mycology and Parasitology.

## COURSE OUTCOME (CO'S)

Establish basic theoretical knowledge in the fields of Mycology and Parasitology. And to study the properties and various infections caused by the fungal, protozoan and helminthes.

## UNIT – I

General Properties of Fungi - Isolation and identification of medically important fungi – diagnosis of fungal disease - routine mycological techniques - antifungal agents

## UNIT – II

Superficial mycosis –Pityriasis versicolor, Tinea nigra, piedra. Cutaneous mycosis – Dermatophytes. Systemic mycosis –Opportunistic mycosis – Candidosis, Cryptococcosis, aspergillosis. Subcutaneous mycosis - Sporotrichosis, Chromoblastomycosis, Mycetoma

## UNIT – III

Introduction to Parasitology - protozoa-amoebae – flagellates - Laboratory techniques in parasitology - Ova, cyst analysis direct and concentration methods. Blood smear examination - antiprotozoan therapy.

## UNIT – IV

Protozoan infections - *Entamoeba histolytica*, *Plasmodium falciparum*, *Leishmania donovani* - *Giardia intestinalis* *Trichomonas vaginalis*, *Toxoplasma gondii*, *Pneumocystis carinii*, *Balantidium coli*.

## UNIT – V

Helminthic infections – *Taenia solium*. *Trematodes* - *Schistosoma haematobium*, Nematodes - *Trichuris trichiura* - *Ascaris lumbricoides*, *Ancylostoma duodenale*, *Wuchereria bancrofti*.

## SUGGESTED READINGS

### TEXT BOOKS

1. Ananthanarayanan, R., and Panicker, C.K.J., (2009). *Text Book of Microbiology*. (8<sup>th</sup> ed.). Orient Longman. New Delhi.
2. Chakraborty, P. (2003). *A Text book of Microbiology*. (2<sup>nd</sup> ed.). New Central Book Agency (P) Ltd., Calcutta.
3. Chander, J. (2002). *A Text book of Medical Mycology*. Interprint Mehta Publishers, New Delhi.
4. Chatterjee, K.D. (1980). *Parasitology in Relation To Medicine*, (12<sup>th</sup> ed.). Chatterjee Medical Publishers, Calcutta.

### REFERENCES

## KARPAGAM ACADEMY OF HIGHER EDUCATION

CLASS: II M.Sc MB

COURSE NAME: MEDICAL MYCOLOGY AND PARASITOLOGY

COURSE CODE: 18MBP303

SYLLABUS

BATCH-2018-2020

1. Chunin, J. (2000). *Parasitology*. New York Publishers, London.
2. Dismukes, W.E., Pappas, P.G., and Sobel, D., (2003). *Clinical Mycology*. Oxford University Press. UK.
3. Jawetz, E., Melnic, J.L., and Adelberg, E.A., (2001). *Review of Medical Microbiology*. (22<sup>nd</sup> ed.). Lange Medical Publishers, New York.
4. Mehrotra, R.S., and Aneja, K.R., (2007). *Introduction to Mycology*. New Age International Ltd, New Delhi.
5. Panjarathinam, R. (2007). *Text book of Medical Parasitology*, (2<sup>nd</sup> ed.). Orient Longman Publishers.
6. Parija, S.C. (2008). *A Text book of Medical Parasitology*. (3<sup>rd</sup> ed.). All India Publishers and Distributors, New Delhi.

**KARPAGAM ACADEMY OF HIGHER EDUCATION**

(Deemed to be University)

(Established Under Section 3 of UGC Act 1956)

**Coimbatore – 641 021.****(For the candidates admitted from 2017 onwards)****DEPARTMENT OF MICROBIOLOGY****SUBJECT NAME: MEDICAL MYCOLOGY AND PARASITOLOGY****SEMESTER: III****SUB.CODE:18MBP303****CLASS: II M.Sc (MB)**

**LECTURE PLAN**  
**DEPARTMENT OF MICROBIOLOGY**

S.No	Lecture Duration Period	Topics to be Covered	Support Material/Page Nos
		<b>UNIT-I</b>	
1	1	General Properties of Fungi	R1:672-675, W1
2	1	General Properties of Fungi	R1:672-675, W1
3	1	Isolation and identification of medically important fungi	R1:676, W1
4	1	Isolation and identification of medically important fungi	R1:676, W1
5	1	Diagnosis of fungal disease	T1:356-357
6	1	Diagnosis of fungal disease	T1:356-357
7	1	Routine mycological techniques	T1:704-710
8	1	Antifungal agents	W2
9	1	Recapitulation and discussion of question	
	<b>Total No of Hours Planned For Unit 1=09</b>		
		<b>UNIT-II</b>	
1	1	Superficial mycosis- Pityriasis versicolor	T2: 612-613, W3
2	1	Tinea nigra, piedra	T2: 612-613, W3
3	1	Cutaneous mycosis	T2: 614-618, W3
4	1	Dermatophytes, Systemic mycosis	T2: 614-618, W3
5	1	Opportunistic mycosis	T2: 624-627, W3
6	1	Candidosis, Cryptococcosis	T2: 624-627, W3
7	1	Aspergillosis. Subcutaneous mycosis	T2: 624-627, W3

8	1	Sporotrichosis, Chromoblastomycosis, Mycetoma	T2: 614-618, W3
9	1	Recapitulation and discussion of question	
	<b>Total No of Hours Planned For Unit II=09</b>		
		<b>UNIT-III</b>	
1	1	Introduction to Parasitology	T3:49,10 – 13
2	1	Protozoa, Amoebae	T3:14 – 15, 36
3	1	Flagellates	T3:14 – 15, 36
4	1	Laboratory techniques in parasitology	T3: 221
5	1	Ova, Cyst analysis Direct and Concentration methods	T3: 223 – 225
6	1	Ova, Cyst analysis Direct and Concentration methods	T3: 223 – 225
7	1	Blood smear examination	T3: 225 – 226-
8	1	Antiprotozoan therapy	T3: 232
9	1	Recapitulation and discussion of question	
	<b>Total No of Hours Planned For Unit III=09</b>		
		<b>UNIT-IV</b>	
1	1	Protozoan infections- <i>Entamoeba histolytica</i>	T3: 15 – 29
2	1	<i>Plasmodium falciparum</i>	T3:61 – 74, 80 – 81
3	1	<i>Leishmania donovani</i>	T3:51 – 62
4	1	<i>Giardia intestinalis</i>	T3:36 – 39
5	1	<i>Trichomonas vaginalis</i>	T3:40 – 41, 96-103
6	1	<i>Toxoplasma gondii</i>	T3:40 – 41, 96-103
7	1	<i>Pneumocystis carinii</i>	T3:108 – 110
8	1	<i>Balantidium coli</i>	T3:112 – 118
9	1	Recapitulation and discussion of question	
	<b>Total No of Hours Planned For Unit IV=09</b>		
		<b>UNIT-V</b>	

1	1	Helminthic infections– <i>Taenia solium</i>	T3:147 – 150
2	1	<i>Taenia solium</i>	T3:147 – 150
3	1	<i>Trematodes Schistosoma haematobium</i>	T3:118- 124
4	1	Nematodes - <i>Trichuris trichiura</i>	T3:159 – 160,165 - 168
5	1	<i>Ascaris lumbricoides</i>	T3:189 – 193
6	1	<i>Ancylostoma duodenale</i>	T3:175 – 182
7	1	<i>Wuchereria bancrofti</i>	T3:197 – 206
8	1	<i>Wuchereria bancrofti</i>	T3:197 – 206
9	1	Recapitulation and discussion of question	
10	1	Old question paper discussion (Last Five years)	
11	1	Old question paper discussion (Last Five years)	
12	1	Old question paper discussion (Last Five years)	
		<b>Total No of Hours Planned for unit V=12</b>	

**SUGGESTED READINGS:**

1. Jawetz, E., J.L. Melnic and E.A. Adelberg, 2001. Review of Medical Microbiology. 22<sup>nd</sup> Edition. Lange Medical Publishers. New York.
2. Fritz, H.Kayser, Kurl-A Bienz, Johaanereckert, Rolf,M. Zinker nagel, MedicalMicrobiology, 2005, Thieme, New York.
3. Ananthanarayanan, R. and C.K.J. Panicker, 2005. Text book of Microbiology. 7<sup>th</sup> Edition. Orient Longman. New Delhi
4. Ananthanarayanan, R. and C.K.J. Panicker, 2009. Text Book of Parasitology. 6<sup>th</sup> Edition. Jaypee brothers medical publishers (p) Ltd, New Delhi.

**WEBSITES**

1. **W1:** [www.microbeonline.com](http://www.microbeonline.com)
2. **W2:** [www.ncbi.nlm.nih.gov](http://www.ncbi.nlm.nih.gov)
3. **W3:** [www.britannica.com](http://www.britannica.com)

**UNIT-I**  
**SYLLABUS**

General Properties of Fungi - Isolation and identification of medically important fungi – diagnosis of fungal disease - routine mycological techniques - antifungal agents

**GENERAL PROPERTIES OF FUNGI**

Fungi grow in two basic forms, as **yeasts** and **molds** (or **moulds**). Growth in the mold form occurs by the production of multicellular filamentous colonies. These colonies consist of branching cylindric tubules called **hyphae**, varying in diameter from 2 to 10  $\mu\text{m}$ . The mass of intertwined hyphae that accumulates during active growth is a **mycelium**. Some hyphae are divided into cells by cross-walls or **septa**, which typically form at regular intervals during hyphal growth. However, members of the Order Mucorales produce hyphae that are rarely septated. Vegetative or substrate hyphae penetrate the supporting medium, anchor the colony, and absorb nutrients. In contrast, aerial hyphae project above the surface of the mycelium and usually bear the reproductive structures of the mold. When a mold is isolated from a clinical specimen, its growth rate, macroscopic appearance, and microscopic morphology are usually sufficient to determine its genus and species. The most helpful phenotypic features are the ontogeny and morphology of the asexual reproductive spores, or conidia.

Yeasts are single cells, usually spherical to ellipsoid in shape and varying in diameter from 3 to 15  $\mu\text{m}$ . Most yeasts reproduce by budding. Some species produce buds that characteristically fail to detach and become elongated; continuation of the budding process then produces a chain of elongated yeast cells called **pseudohyphae**. Yeast colonies are usually soft, opaque, 1–3 mm in size, and cream-colored. Because the colonies and microscopic morphology of many yeasts are quite similar, yeast species are identified on the basis of physiologic tests and a few key morphologic differences. Some species of fungi are dimorphic and capable of growth as a yeast or mold depending on environmental conditions. Fungi have an essential rigid **cell wall** that determines their shape and protects them from osmotic and environmental stress. Cell walls are composed largely of carbohydrate layers—long chains of polysaccharides—as well as glycoproteins and lipids. Some sugar polymers are found in the cell walls of many fungi, such as chitin (an unbranched polymer of  $\beta$ -1,4-linked *N*-acetylglucosamine); glucans, which are glucose polymers (eg,  $\beta$ -1,3-glucan and  $\beta$ -1,6-glucan); and mannans, polymers of mannose (eg,  $\alpha$ -1,6-mannose). In addition, other polysaccharides may be unique to specific fungal species. During infection, fungal cell walls exert important pathobiologic properties. The surface components of the cell wall mediate attachment of the fungus to host cells. Specific fungal cell wall moieties bind to pattern recognition receptors on host cell membranes, such as certain toll-like receptors, to stimulate innate immune responses. Cell wall glucans and other polysaccharides may activate the complement cascade and provoke an inflammatory reaction. Most of these polysaccharides are poorly degraded by the host and can be detected with special histologic stains. Cell walls also release immunodominant antigens that may elicit cellular immune responses and diagnostic antibodies. In addition, some yeasts and molds have melanized cell walls, which impart a brown or black pigment to the fungal colony. Such fungi are **dematiaceous**.

Several studies have shown that melanin protects these fungi from host defenses and is associated with virulence. The life cycles of fungi are remarkably versatile. Depending on the fungal species, the predominant nuclear chromosomal count may be haploid or diploid. Some species exist entirely by clonal growth or asexual reproduction, and barring spontaneous mutations, every cell will be a genetic clone. Other species are capable of sexual reproduction, which may or may not require genetically different

partners for mating and meiosis. Asexual as well as sexual reproduction can result in the production of **spores**, which enhance fungal survival. Spores are usually dormant, readily dispersed, more resistant to adverse conditions, and germinate to form vegetative cells when conditions for growth are favorable. Spores derived from asexual or sexual reproduction are termed anamorphic or teleomorphic states, respectively. Like vegetative cells, asexual spores are mitotic progeny (ie, mitospores). The medical fungi produce two major types of asexual spores, **conidia**, which are produced by most pathogenic fungi, and, in the Order Mucorales, **sporangiospores** (see below and Glossary). Informative features of spores include their ontogeny (some molds produce complex conidiogenic structures) as well as their morphology (size, shape, texture, color, and unicellularity or multicellularity).

In some fungi, vegetative cells may transform into conidia (eg, arthroconidia, chlamydospores). In others, conidia are produced by a conidiogenous cell, such as a phialide, which itself may be attached to a specialized hypha called a conidiophore. Sporangiospores result from mitotic replication and spore production within a sac-like structure called a sporangium, which is supported by a sporangiophore.

### **ISOLATION AND IDENTIFICATION OF MEDICALLY IMPORTANT FUNGI**

Besides fungal allergies (e.g., extrinsic allergic alveolitis) and mycotoxicoses (aflatoxicosis), fungal infections are by far the most frequent fungal diseases. Mycoses are classified clinically as follows:

- Primary mycoses (coccidioidomycosis, histoplasmosis, blastomycoses).
- Opportunistic mycoses (surface and deep yeast mycoses, aspergillosis, mucormycoses, phaeohyphomycoses, hyalohyphomycoses, cryptococcoses; penicilliosis, pneumocystosis).
- Subcutaneous mycoses (sporotrichosis, chromoblastomycosis, Madura foot (mycetoma)).
- Cutaneous mycoses (pityriasis versicolor, dermatomycoses).

Little is known about fungal pathogenicity factors. The natural resistance of the macroorganism to fungal infection is based mainly on effective phagocytosis whereas specific resistance is generally through cellular immunity. Opportunistic mycoses develop mainly in patients with immune deficiencies (e.g., in neutropenia). Laboratory diagnostic methods for fungal infections mostly include microscopy and culturing, in order to detect the pathogens directly, and identification of specific antibodies. Therapeutics for treatment of mycoses include polyenes (above all amphotericin B), azoles (e.g., itraconazole, fluconazole, voriconazole), allylamines, antimetabolites (e.g., 5-fluorocytosine), and echinocandins (e.g., caspofungin). Antimycotics are often administered in combination.

The primary concern here is identification of the pathogen.

#### **Microscopy:**

Native preparation: briefly heat material under coverslip with 10% KOH. Stained preparation: stain with methylene blue, lactophenol blue, periodic acid-Schiff (PAS), ink, etc.

#### **Culturing**

This is possible on universal and selective mediums. Sabouraud dextrose agar can contain selective agents (e.g., chloramphenicol and cycloheximide), this medium has an acid pH of 5.6. The main identifying structures are morphological, in particular the asexual and, if present, sexual reproductive structures. Biochemical tests are used mainly to identify yeasts and are generally not as important in mycology as they are in bacteriology.

#### **Serology:**

By the identification of antibodies to special fungal antigens in patient's serum. The Interpretation of serological findings is quite difficult in fungal infections. & Antigen detection. By finding of specific antigens in the diagnostic material by direct means using known antibodies, possible in some fungal infections (e.g., cryptococcosis).



**Cutaneous test:**

Cutaneous (allergy) tests with specific fungal antigens can be useful in diagnosing a number of fungal infections.

**Nucleic acid detection:**

Combined with amplification, such tests are useful for rapid detection of mycotic diseases in immunocompromised patients.

**OVERVIEW OF THE MOST IMPORTANT MYCOSES IN HUMANS**

Disease	Etiology	Remarks
<b>Primary mycoses</b> (do not occur endemic in Europe)		
Coccidioidomycosis	<i>Coccidioides immitis</i>	Pulmonary mycosis. Inhalation of spores. Southwestern US and South America
Histoplasmosis	<i>Histoplasma capsulatum</i>	Pulmonary mycosis. Inhalation of spores. Dissemination into RES. America, Asia, Africa
North American Blastomycosis	<i>Blastomyces dermatitidis</i>	Primary pulmonary mycosis. Secondary dissemination (dermal). North America, Africa
South American Blastomycosis	<i>Paracoccidioides brasiliensis</i>	Primary pulmonary mycosis. Secondary dissemination
<b>Opportunistic mycoses</b>		
Candidiasis (soor)	<i>Candida albicans</i> , other <i>Candida</i> sp.	Endogenous infection. Primary infection of mucosa and skin with secondary dissemination
Aspergillosis	<i>Aspergillus fumigatus</i> (90 %); other <i>Aspergillus</i> sp.	Aspergilloses of the respiratory tract, endophthalmitis; aspergillosis of CNS; septic aspergillosis
Cryptococcosis	<i>Cryptococcus neoformans</i> (yeast; thick capsule)	Aerogenic infection. Pulmonary cryptococcosis. Secondary dissemination into CNS
Mucormycosis (zygomycosis)	<i>Mucor</i> spp.; <i>Rhizopus</i> spp.; <i>Absidia</i> spp.; <i>Cunninghamella</i> spp., and others	Rhinocerebral, pulmonary, gastrointestinal, cutaneous mucormycosis
Phaeohyphomycosis (caused by "dematiaceous" or "black" fungi)	Over 100 species discovered to date, e.g., <i>Curvularia</i> spp.; <i>Bipolaris</i> spp.; <i>Alternaria</i> spp. Melanin integrated in cell wall	Subcutaneous infections, paranasal sinus infections, infections of the CNS, sepsis also possible
Pneumocystosis	<i>Pneumocystis carinii</i>	Defective cellular immunity



Disease	Etiology	Remarks
Hyalohyphomycoses (caused by colorless [hyaline] molds)	More than 40 species discovered to date, e.g., <i>Fusarium</i> spp.; <i>Scedosporium</i> spp.; <i>Paecilomyces lilacinus</i>	Infections of cornea and eye, pneumonia, osteomyelitis, arthritis, soft tissue infections, sepsis also possible
Yeast mycoses (except candidiasis)	<i>Torulopsis glabrata</i> ; <i>Trichosporon beigeli</i> ; <i>Rhodotorula</i> spp.; <i>Malassezia furfur</i> , and others	Infections of various organs in immunosuppressed patients. Sepsis also possible. <i>Malassezia</i> <i>furfur</i> in catheter sepsis in neonates and in intravenous feeding with lipids
Penicilliosis	<i>Penicillium marneffei</i>	Most frequent opportunistic infection in AIDS patients in Southeast Asia. Primary infection focus in lungs
<b>Subcutaneous mycoses</b>		
Sporotrichosis	<i>Sporothrix schenckii</i>	Dimorphic fungus, ulcerous lesions on extremities
Chromoblastomycosis	<i>Phialophora verrucosa</i> <i>Fonseca pedrosoi</i> <i>Cladosporium carrionii</i> , etc.	Black molds. Wartlike pigmented lesions on extremities. Tropical disease
Madura foot (mycetoma)	<i>Madurella mycetomi</i> <i>Scedosporium</i> <i>apiospermum</i> , etc.	Subcutaneous abscesses on feet or hands. Can also be caused by bacteria (see p. 273). In tropics and subtropics
<b>Cutaneous mycoses</b>		
Pityriasis (or tinea versicolor)	<i>Malassezia furfur</i>	Surface infection; relatively harmless; pathogen is dependent on an outside source of fatty acids
Dermatomycoses Tinea pedis, T. cruris, T. capitis, T. barbae, T. unguinum, T. corporis	<i>Trichophyton</i> spp. <i>Microsporum</i> spp. <i>Epidermophyton</i> spp.	All dermatophytes are filamen- tous fungi (hyphomycetes). Anthropophilic, zoophilic, geophilic species. Always transmitted by direct or indirect contact

### Diagnosis of fungal disease and Routine mycological techniques

#### Collection of specimens:

- Skin specimens - clean with 70% alcohol to remove dirt, oil and surface saprophytes.
- Nails - cleaned same as skin. Usually clipped; need to be finely minced before inoculating to media.

- Hair - obtained from edge of infected area of scalp; hair can be obtained by plucking, brushing, or with a sticky tape. A Wood's lamp can be helpful in locating infected areas.
- Body fluids - normal sterile collection procedures
- Skin specimens - clean with 70% alcohol to remove dirt, oil and surface saprophytes.
- Nails - cleaned same as skin. Usually clipped; need to be finely minced before inoculating to media.
- Hair - obtained from edge of infected area of scalp; hair can be obtained by plucking, brushing, or with a sticky tape. A Wood's lamp can be helpful in locating infected areas.
- Body fluids - normal sterile collection procedures
- Preparation of specimens for transport:
- Hair & nails sent in a dry envelope, inside proper container.
- Other specimens are usually sent frozen or on dry ice.
- Packaging - must meet biohazard regulations. Cultures must be on tubed media (not plates).
- Inside labeling information: patient ID, specimen source, suspected organism.
- Outside labeling - WARNING: POTENTIAL PATHOGEN.

**Processing of specimen to recover fungus:**

Skin, nails, & hair - direct exam following KOH preparation.

**Body fluids -**

**CSF** - centrifuged; examine sediment microscopically, inoculate media.

Pleural fluid, sputum, and bronchial aspiration - specimen must be fresh as saprophytes would overgrow pathogens such as *H. capsulatum*. Specimens may be refrigerated up to 2 hours.

**Gastric washings** - same as for pleural fluids.

**Genito-urinary specimens** - first morning specimen preferred; centrifuge & inoculate on media.

**Blood/bone marrow** - inoculate to BHI broth and BHI slant.

**Wound abscess or drainage** - culture anaerobically if actinomycosis is suspected.

**Tissue specimens** - examine for pus, caseous material or granules; mince aseptically, inoculate on media

**Direct examination of specimens:**

Direct exam required on any biological material sent to lab for fungus culture. Examine for spores, hyphae, mycelial elements, budding yeast, mycotic granules.

**Wet mount** - good for yeast; examination is done in natural environment, so loss of fragile structure is minimal.

**KOH** - done on skin scrapings, hair, nails, sputum, vaginal specimens. KOH clears tissue cells so fungal elements may be seen.

**Stains used:**

**Lactophenol Cotton Blue** - very popular for quick evaluation of fungal structures; stains chitin in cell walls of fungi.

**Periodic Acid - Schiff Stain (PAS)** - stains polysaccharide in the cell wall of fungi. Fungi stain pink-red with blue nuclei.

**Gomori Methenamine Silver Stain** - silver nitrate outlines fungi in black due to the silver precipitating on the fungi cell wall.

**Gridley Stain** - Hyphae and yeast stain dark blue or rose. Tissues stain deep blue and background is yellow.

**Mayer Mucicarmine Stain** - will stain capsules of *Cryptococcus neoformans* deep rose.

**Fluorescent Antibody Stain** - extremely specific method of detecting fungi in tissues or fluids.

**Papanicolaou Stain** - good for initial differentiation of dimorphic fungi. Works well on sputum smears.

**Gram Stain** - generally fungi are gram positive; but Actinomyces and Nocardia are gram variable.

**Acid-Fast Stain** - used to differentiate the acid-fast Nocardia from other aerobic Actinomyces.

**Giemsa Stain** - used for blood and bone marrow specimens.

**India Ink** - demonstrates the capsule of *Cryptococcus neoformans* in CSF specimens.

**Fungal Culturing:**

- Tubed media is used rather than plated media.
- Less chance for spore release into the environment.
- Less chance for dehydration.
- Easier storage.
- The agar in a tube is inoculated in a straight line. Preliminary identification is based on differential growth patterns on various media

**Fungal Culturing:**

**Media -**

- Sabouraud's dextrose agar - classic medium, recommended for most studies.
- Sabouraud's dextrose agar with chloramphenicol (inhibits bacterial growth).
- Mycosel agar - a commercially produced agar containing chloramphenicol to inhibit bacterial growth, and cycloheximide to inhibit saprophytic fungi and some yeasts (including *C. neoformans*).
- *Aspergillus* and *Scopulariopsis* are opportunistic pathogens. Cycloheximide will prevent their growth. Bacteria-like fungi (such as Actinomycetes) are inhibited by chloramphenicol.
- Brain heart infusion slant (BHI) - more enriched than Sab-Dex. For recovery of *H. capsulatum*.
- Potato-dextrose agar (PDA) and Corn-meal agar - used in slide cultures to induce spore formation, which aids in identification

**Special applications agar -**

- Caffeic Acid Agar - *Cryptococcus neoformans* will produce melanin resulting in black colonies (must protect media from light).
- Birdseed Agar - used to isolate *Cryptococcus neoformans* from contaminated cultures.
- KT Medium & Kelley Agar - used to convert dimorphic fungus *Blastomyces dermatitidis* from mycelial to yeast form.
- Modified Converse Liquid Medium (Levine's) - used to promote spherule production by *Coccidioides immitis*.

**Fungal growth requirements -**

- Atmosphere - True fungi are aerobic but there are a few anaerobes among the bacteria-like fungi.
- Time - Some yeasts grow overnight. Saprophytes are fast growers (several days). Generally cultures are held at least 4 weeks.
- *Paracoccidioides brasiliensis* may require 4-5 weeks; 10 weeks are recommended if *Histoplasma capsulatum* is suspected.
- Routine cultures should be examined every other day.

**Colony Morphology (macroscopic features):**

- **Surface topography** - some fungal colonies may be free growing, covering the entire surface of agar; others may grow in a restricted manner.

- **Surface texture** - cottony or wooly (floccose), granular, chalky, velvety, powdery, silky, glabrous (smooth, creamy), or waxy

**Pigmentation** - Fungi may be colorless or brightly colored. Color may be on fungus itself, on its sporulating apparatus, on the agar, or on the bottom of the colony (reverse pigmentation).

**Mycelium** -

- Vegetative mycelium - provides nutrition.
- Aerial mycelium – reproductive

**Microscopic evaluation:**

- **Teased Preparation** - wet mount
- **Slide Culture** - gives undisturbed microscopic morphology.
- **Cellophane Tape Preparation.**

**Biochemical studies** - used to ID yeast and yeast-like organisms.

**Carbohydrate fermentation** -

Growth and utilization of a carbohydrate under anaerobic conditions as determined by acid and gas production. Specimen is inoculated beneath the broth. Bromcresol purple is the indicator. Acid production turns purple to yellow. Gas is detected by appearance of bubbles trapped in the fermentation tube. Observe every 48 hours for 14 days.

**Carbohydrate assimilation** -

Determines ability to utilize a carbohydrate as sole source of carbon. Bromcresol purple indicator turns from purple to yellow. Tubes unchanged (as determined by comparing to a blank tube) after 10 days are negative.

**Nitrogen assimilation** -

Utilizes 3 tubes with differing sources of nitrogen. Bromthymol blue is the indicator (blue to yellow is positive).

**Growth on specific agars:**

**Christensen's urea agar** - Urea is hydrolyzed by some yeast to form ammonia (pH increases) which turns media from yellow to dark pink.

Caffeic acid medium (must protect media from light) - Production of melanin by *Cryptococcus neoformans* resulting in black colonies.

**Other tests:**

**Germ tube** - *Candida albicans* & *Candida stellatoidea* produce germ tubes when incubated in a protein medium.

**Demonstration of chlamydospores** - Yeast is inoculated by jabbing appropriate agar (Cornmeal with tween 80) and observed every 24 hours for 3 days for chlamydospore production.

**Hypersensitivity:** (skin tests and serological tests)

**Skin tests** - demonstrates T-cell immunity (cellular) to a fungus.

**Serological tests** - demonstrates B-cell immunity (humoral) to a fungus; sera should be drawn in pairs (acute and convalescent).

## **ANTIFUNGAL CHEMOTHERAPY**

A limited but increasing number of antibiotics can be used to treat mycotic infections. Most have one or more limitations, such as profound side effects, a narrow antifungal spectrum, poor penetration of certain tissues, and the selection of resistant fungi. Finding suitable fungal targets is difficult because fungi, like



humans, are eukaryotes. Many of the cellular and molecular processes are similar, and there is often extensive homology among the genes and proteins.

The classes of currently available drugs include the polyenes (amphotericin B and nystatin), which bind to ergosterol in the cell membrane; flucytosine, a pyrimidine analog; the azoles and other inhibitors of ergosterol synthesis, such as the allylamines; the echinocandins, which inhibit the synthesis of cell wall  $\beta$ -glucan; and griseofulvin, which interferes with microtubule assembly. Currently under investigation are inhibitors of cell wall synthesis, such as nikkomycin and pradimicin, and sordarin, which inhibits elongation factor 2. In recent years, the number of antifungal drugs has increased, and additional compounds are currently under evaluation in clinical trials. Many of the newer chemotherapeutics are variations of the azole class of fungistatic drugs, such as the triazoles voriconazole and posaconazole. These drugs and the newer compounds were designed to improve the antifungal efficacy and pharmacokinetics, as well as to reduce the adverse side effects.

### **Amphotericin B**

#### **A. Description**

The major polyene antibiotic is amphotericin B, a metabolite of streptomyces. Amphotericin B is the most effective drug for severe systemic mycoses. It has a broad spectrum, and the development of resistance is rare. The mechanism of action of the polyenes involves the formation of complexes with ergosterol in fungal cell membranes, resulting in membrane damage and leakage. Amphotericin B has greater affinity for ergosterol than cholesterol, the predominant sterol in mammalian cell membranes. Packaging of amphotericin B in liposomes and lipoidal emulsions has shown superb efficacy and excellent results in clinical studies. These formulations are currently available and may replace the conventional preparation.

The lipid preparations are less toxic and permit higher concentrations of amphotericin B to be used.

#### **B. Mechanism of Action**

Amphotericin B is given intravenously as micelles with sodium deoxycholate dissolved in a dextrose solution. Though the drug is widely distributed in tissues, it penetrates poorly to the cerebrospinal fluid. Amphotericin B firmly binds to ergosterol in the cell membrane. This interaction alters the membrane fluidity and perhaps produces pores in the membrane through which ions and small molecules are lost. Unlike most other antifungals, amphotericin B is cidal. Mammalian cells lack ergosterol and are relatively resistant to these actions. Amphotericin B binds weakly to the cholesterol in mammalian membranes, and this interaction may explain its toxicity. At low levels, amphotericin B has an immunostimulatory effect.

#### **C. Indications**

Amphotericin B has a broad spectrum with demonstrated efficacy against most of the major systemic mycoses, including coccidioidomycosis, blastomycosis, histoplasmosis, sporotrichosis, cryptococcosis, aspergillosis, mucormycosis, and candidiasis. The response to amphotericin B is influenced by the dose and rate of administration, the site of the mycotic infection, the immune status of the patient, and the inherent susceptibility of the pathogen. Penetration of the joints and the central nervous system is poor, and intrathecal or infections. Amphotericin B is used in combination with flucytosine to treat cryptococcosis. Some fungi, such as *Pseudallescheria boydii* and *Aspergillus terreus*, do not respond well to treatment with amphotericin B.

#### **D. Side Effects**

All patients have adverse reactions to amphotericin B, though these are greatly diminished with the new lipid preparations. Acute reactions that usually accompany the intravenous administration of amphotericin B include fever, chills, dyspnea, and hypotension. These effects can usually be alleviated by

prior or concomitant administration of hydrocortisone or acetaminophen. Tolerance to the acute side effects develops during therapy. Chronic side effects are usually the result of nephrotoxicity. Azotemia almost always occurs with amphotericin B therapy, and serum creatinine and ion levels must be closely monitored. Hypokalemia, anemia, renal tubular acidosis, headache, nausea, and vomiting are also frequently observed. While some of the nephrotoxicity is reversible, permanent reduction in glomerular and renal tubular function does occur. This damage can be correlated with the total dose of amphotericin B given. Toxicity is greatly diminished with the lipid formula ions of amphotericin B (ie, Abelcet, Amphotec, and AmBisome).

### **Flucytosine**

#### **A. Description**

Flucytosine (5-fluorocytosine) is a fluorinated derivative of cytosine. It is an oral antifungal compound used primarily in conjunction with amphotericin B to treat cryptococcosis or candidiasis. It is effective also against many dematiaceous fungal infections. It penetrates well into all tissues, including cerebrospinal fluid.

#### **B. Mechanism of Action**

Flucytosine is actively transported into fungal cells by a permease. It is converted by the fungal enzyme cytosine deaminase to 5-fluorouracil and incorporated into 5-fluorodeoxyuridylic acid monophosphate, which interferes with the activity of thymidylate synthetase and DNA synthesis. Mammalian cells lack cytosine deaminase and are therefore protected from the toxic effects of fluorouracil. Unfortunately, resistant mutants emerge rapidly, limiting the utility of flucytosine.

#### **C. Indications**

Flucytosine is used mainly in conjunction with amphotericin B for treatment of cryptococcosis and candidiasis. In vitro, it acts synergistically with amphotericin B against these organisms, and clinical trials suggest a beneficial effect of the combination, particularly in cryptococcal meningitis. The combination has also been shown to delay or limit the emergence of flucytosine-resistant mutants. By itself, flucytosine is effective against chromoblastomycosis and other dematiaceous fungal infections.

#### **D. Side Effects**

While flucytosine itself probably has little toxicity for mammalian cells and is relatively well tolerated, its conversion to fluorouracil results in a highly toxic compound that is probably responsible for the major side effects. Prolonged administration of flucytosine results in bone marrow suppression, hair loss, and abnormal liver function. The conversion of flucytosine to fluorouracil by enteric bacteria may cause colitis. Patients with AIDS may be more susceptible to bone marrow suppression by flucytosine, and serum levels should be closely monitored.

### **Azoles**

#### **A. Description**

The antifungal imidazoles (eg, ketoconazole) and the triazoles (fluconazole, voriconazole, and itraconazole) are oral drugs used to treat a wide range of systemic and localized fungal infections. The indications for their use are still being evaluated, but they have already supplanted amphotericin B in many less severe mycoses because they can be administered orally and are less toxic.

#### **B. Mechanism of Action**

The azoles interfere with the synthesis of ergosterol. They block the cytochrome P450-dependent 14 $\alpha$ -demethylation of lanosterol, which is a precursor of ergosterol in fungi and cholesterol in mammalian cells. However, the fungal cytochrome P450s are approximately 100–1000 times more sensitive to the azoles than mammalian systems. The various azoles are designed to improve their efficacy, availability, and pharmacokinetics and reduce their side effects. These are fungistatic drugs.



### **C. Indications**

The indications for the use of antifungal azoles will broaden as the results of long-term studies—as well as new azoles—become available. Accepted indications for the use of antifungal azoles are listed below. Ketoconazole is useful in the treatment of chronic mucocutaneous candidiasis, dermatophytosis, and nonmeningeal and histoplasmosis. Of the various azoles, fluconazole offers the best penetration of the central nervous system. It is used as maintenance therapy for cryptococcal and coccidioidal meningitis. Oropharyngeal candidiasis in AIDS patients and candidemia in immunocompetent patients can also be treated with fluconazole. Itraconazole is now the agent of first choice for histoplasmosis and blastomycosis as well as for certain cases of coccidioidomycosis, paracoccidioidomycosis, and aspergillosis. It has also been shown to be effective in the treatment of chromomycosis and onychomycosis due to dermatophytes and other molds. Voriconazole, which can be given orally or intravenously, exhibits a broad spectrum of activity against many molds and yeasts, especially aspergillosis, fusariosis, pseudallescheriasis, and other less common systemic pathogens. The newest triazole is posaconazole, which has a wide spectrum and demonstrated efficacy against fluconazole-resistant *Candida* species, aspergillosis, mucormycosis, and other opportunistic invasive molds. It is also well tolerated.

### **D. Side Effects**

The adverse effects of the azoles are primarily related to their ability to inhibit mammalian cytochrome P450 enzymes. Ketoconazole is the most toxic, and therapeutic doses may inhibit the synthesis of testosterone and cortisol, which may cause a variety of reversible effects such as gynecomastia, decreased libido, impotence, menstrual irregularity, and occasionally adrenal insufficiency. Fluconazole and itraconazole at recommended therapeutic doses do not cause significant impairment of mammalian steroidogenesis. All the antifungal azoles can cause both asymptomatic elevations in liver function tests and rare cases of hepatitis. Voriconazole causes reversible visual impairment in about 30% of patients. Since antifungal azoles interact with P450 enzymes that are also responsible for drug metabolism, some important drug interactions can occur. Increased antifungal azole concentrations can be seen when isoniazid, phenytoin, or rifampin is used. Antifungal azole therapy can also lead to higher than expected serum levels of cyclosporine, phenytoin, oral hypoglycemics, anticoagulants, digoxin, and probably many others. Serum monitoring of both drugs may be necessary to achieve a proper therapeutic range.

### **Echinocandins**

The echinocandins are a new class of antifungal agents that perturb the synthesis of the pervasive cell wall polysaccharide  $\beta$ -glucan by inhibiting 1,3- $\beta$ -glucan synthase and disrupting cell wall integrity. The first licensed drug, caspofungin, has shown efficacy against invasive aspergillosis and systemic candidiasis due to a wide range of *Candida* species. This intravenous agent may be especially indicated for refractory aspergillosis. Caspofungin is well tolerated. Similar to caspofungin, two newly approved echinocandins, micafungin and anidulafungin, also inhibit the synthesis of  $\beta$ -glucan and have a similar spectrum of activity against species of *Candida* and *Aspergillus*, as well as several other molds. Micafungin and anidulafungin were recently licensed for the treatment of esophageal candidiasis and for the antifungal prophylaxis of hematopoietic stem cell transplant patients. Both seem to have better pharmacokinetics and in vivo stability than caspofungin. Clinical studies suggest that they will be useful in the treatment of mucosal and systemic candidiasis, refractory invasive aspergillosis, and in combination with amphotericin B or some of the newer triazoles.

### **Griseofulvin**

Griseofulvin is an orally administered antibiotic derived from a species of penicillium. It is used to treat dermatophytoses and must be given for long periods. Griseofulvin is poorly absorbed and concentrated in

the stratum corneum, where it inhibits hyphal growth. It has no effect on other fungi. After oral administration, griseofulvin is distributed throughout the body but accumulates in the keratinized tissues. Within the fungus, griseofulvin interacts with microtubules and disrupts mitotic spindle function, resulting in inhibition of growth. Only actively growing hyphae are affected. Griseofulvin is clinically useful for the treatment of dermatophyte infections of the skin, hair, and nails. Oral therapy for weeks to months is usually required. Griseofulvin is generally well tolerated. The most common side effect is headache, which usually resolves without discontinuation of the drug. Less frequently observed side effects are gastrointestinal disturbances, drowsiness, and hepatotoxicity.

### **Terbinafine**

Terbinafine is an allylamine drug; it blocks ergosterol synthesis by inhibiting squalene epoxidase. Terbinafine is given orally to treat dermatophyte infections. It has proved quite effective in treating nail infections as well as other dermatophytoses. Side effects are not common but include gastrointestinal distress, headaches, skin reactions, and loss of sense of taste. For the long-term treatment of tinea unguium, terbinafine—as well as itraconazole and fluconazole—may be given intermittently, using a pulse treatment protocol.

## **TOPICAL ANTIFUNGAL AGENTS**

### **Nystatin**

Nystatin is a polyene antibiotic, structurally related to amphotericin B and having a similar mode of action. It can be used to treat local candidal infections of the mouth and vagina. Nystatin may also suppress subclinical esophageal candidiasis and gastrointestinal overgrowth of candida. No systemic absorption occurs, and there are no side effects. However, nystatin is too toxic for parenteral administration.

### **Clotrimazole, Miconazole, and Other Azoles**

A variety of antifungal azoles too toxic for systemic use are available for topical administration. Clotrimazole and miconazole are available in several formulations. Econazole, butoconazole, tioconazole, and terconazole are also available. All of these compounds seem to have comparable efficacy. Topical azoles have a broad spectrum of activity. Tinea pedis, tinea corporis, tinea cruris, tinea versicolor, and cutaneous candidiasis respond well to local application of creams or powders. Vulvovaginal candidiasis can be treated with vaginal suppositories or creams. Clotrimazole is also available as an oral troche for treatment of oral and esophageal thrush in immunocompetent patients.

### **Other Topical Antifungal Agents**

Tolnaftate and naftifine are topical antifungal agents used in the treatment of many dermatophyte infections and tinea versicolor. Formulations available include creams, powders, and sprays. Undecylenic acid is available in several formulations for the treatment of tinea pedis and tinea cruris. Although it is effective and well tolerated, antifungal azoles, naftifine, and tolnaftate are more effective. Haloprogin and ciclopirox are other topical agents commonly used in dermatophyte infections.

---

**Possible Questions**

**Part B (Two marks)**

1. Define fungi.
2. Define Medical Mycology.
3. Define hyphae.
4. Define pseudo hyphae.
5. What is dematiaceous?
6. List out some medically important fungi.

**Part B (Eight marks)**

1. Explain in detail about medically important fungi.
  2. Explain the general properties of fungi.
  3. Discuss about methods used for the identification of medically important fungi.
  4. Discuss about the various methods used for the isolation of medically important fungi.
  5. Discuss about the various methods used for the microscopic observation of fungi.
  6. How will you diagnose the fungal infection?
  7. Comment on Antifungal agents.
  8. Discuss about specimen collection for fungal infection.
  9. How will you collect and process the specimen?
  10. Discuss in detail about the routine mycological techniques.
  11. Explain the mode of action of Amphotericin B.
  12. Explain the mode of action and side effects of Flucytosine
  13. Write a detailed note on some of the topical antifungal agents?
  14. Describe detail about Azoles.
-

Sn o	Unit I Question	Option 1	Option 2	Option 3	Option 4	Answer
1	The Fungi may be .....	Unicellular	Multicellular	Unicellular Multicellular	Unicellular & Multicellular	Unicellular / Multicellular
2	Fungal cell elongation produces a tubular, thread-like structure known as .....	Mycelium	Hypha	Budding	Filament	Hypha
3	A tangled mass of hyphae constitute .....	Mycelium	Basidium	Conidium	Pseudomycelium	Mycelium
4	Mycelia forming fungi are called .....	Basidiomycetes	Deuteromycetes	Moulds	Cladophora	Moulds
5	Depending on cell morphologies, fungi can be divided into ..... classes	Two	Three	Four	Five	Four
6	The only pathogenic yeast is .....	Cryptococcus sp	Cryptococcus neoformans	Saccharomyces sp	Saccharomyces cerevisiae	Cryptococcus neoformans
7	Moulds form .....	True mycelia	Pseudomycelia	Heteromycelia	Hyphae	True mycelia
8	Dermatophytes are examples of .....	Yeast	Yeast-like fungi	Moulds	Dimorphic fungi	Moulds
9	Dimorphic fungi can occur as .....	Filaments	Yeasts	Filaments or Yeasts	Moulds	Filaments or Yeasts
10	In host tissues or in cultures at ..... temperature, the dimorphic fungi occur as yeasts.	32 °C	35 °C	37 °C	40 °C	37 °C
11	Most fungi are soil .....	Parasites	Saprophytes	Obligate Parasites	Obligate Saprophytes	Saprophytes

12	Modern advanced treatments include .....	Antibiotics	Crude compound	non Immunosuppressive	Active compound	Antibiotics
13	The cell wall of fungi contain .....	Chitin	Mannan	Polysaccharides	Lignin	Mannan
14	The Cytoplasmic membrane of fungi contain .....	Sterols	Calcium pectate	Pectin	Silicate	Sterol
15	Fungal division takes place by	Sexually	Asexually	both Sexually and Asexually	Vegetatively	both Sexually and Asexually
16	Except one, the remaining belong to fungal class.	Yeast	Dimorphic fungi	Moulds	Cladophora	Dimorphic fungi
17	Yeasts are ..... fungi.	Unicellular	Multicellular	Filamentous	Mycelial	Unicellular
18	Yeasts reproduce by .....	Budding	Conidia formation	Spore formation	Mycelial formation	Budding
19	The elongated cells of yeast-like fungi that resemble hyphae are known as _____	Mycelium	Pseudomycelium	Hyphae	Pseudohyphae	Pseudomycelium
20	Fungal cultures are incubated at a temperature of ..... for days	32 °C	35 °C	36 °C	37 °C	37 °C
21	Growth characteristics useful for identification of fungi include .....	Moisture	Colour	temperature	odour	temperature
22	Pigmentation is the character observed on the ..... side of the fungal colony.	Periphery	Reverse	Rotate	Center	Reverse
23	..... forms an important diagnostic feature	Mutant	Presence / absence of septa	Colony	Formation of Pseudohyphae	Presence / absence of septa

	in the identification of fungi.					
24	Which spore is on a club and results from the fusion of two nuclei from different strains of the same fungi?	Ascospore	Basidiospore	Blastospore	Conidiospore	Basidiospore
25	_____ produce basidiospores.	Slime molds	Dimorphic fungi	Club fungi	Sac fungi	Club fungi
26	Which of the following does not represent a human disease caused by fungi?	Ringworm	Cryptococcosis	Malaria	Jock itch	Malaria
27	Fungi that lack partitions (septa) are called	hyphae	coenocytic	yeast	conidia	coenocytic
28	_____ exhibit yeast-like growth at human body temperatures and mold-like growth at room temperature.	Dimorphic fungi	Black bread molds	Sac fungi	Water molds	Dimorphic fungi
29	_____ produce motile sexual and asexual spores.	Slime molds	Dimorphic fungi	Club fungi	Water molds	Water molds
30	In the soil and in cultures at ..... temperature, the dimorphic fungi appear as moulds.	18 °C	20 °C	22 °C	24 °C	22 °C
31	Dimorphic fungi mostly cause ..... infections	systemic	non-systemic	Cutaneous	Sub cutaneous	systemic
32	Based on the sexual spore formation, the fungi is classified into ..... classes.	Three	Four	Five	Six	Four
33	Phycomycetes have	Septate hypha and endogenous	Non-Septate hypha and	Septate hypha and exogenous asexual spores	Non-septate hypha and exogenous	Non-Septate hypha and



		asexual spores	endogenous asexual spores		asexual spores	endogenous asexual spores
34	Phycomycetes produce sexual spores known as .....	Oospores	Ascospores	Basidiospores	Zygospore	Oospores
35	Asexual spores called sporangiospores is observed in ..... Fungi	Phycomycetes	Ascomycetes	Basidiomycetes	Deuteromycetes	Phycomycetes
36	The sexual spores formed by Ascomycetes are known as .....	Sporangiospores	Ascospores	Basidiospores	Zygospore	Ascospores
37	The asexual spores of higher fungi include .....	Sporangiospores	Conidia	Basidiospores	Zygospore	Conidia
38	Ascospores are formed within a sac known as .....	Sporangia	Basidia	Ascus	Conidia	Ascus
39	The sexual spores of basidiomycetes are known as .....	Sporangiospores	Ascospores	Zygospores	Basidiospores	Basidiospores
40	The name fungi imperfective is given to ..... class of fungi	Phycomycetes	Ascomycetes	Basidiomycetes	Deuteromycete	Deuteromycete
41	Mycotic poisoning is of ..... types	One	Two	Three	Four	Two
42	Mycetism causes .....	Gastrointestinal disease	Pulmonary disease	Urinary disease	Intestinal disease	Gastrointestinal disease
43	Psilocybin is produced by .....	Pilobolus	Psilocybe	Mucor	Rhizopus	Psilocybe
44	The best known mycotoxin is .....	Aflatoxin	Victorin	Alkaloid	Terpenoids	Aflatoxin
45	Ergosterol is a .....	Steroid	Protein	Carbohydrat	Fat	Steroid

46	Imidazoles and bistrizoles belong to	Polyene antibiotics	Azole antibiotics	Allylamine antibiotics	Fungistatic antibiotics	Azole antibiotics
47	Special hyphal structures resembling tennis racquets is known as .....	Spiral hyphae	Racquet hyphae	Favic chandelier	Filamentous hyphae	Racquet hyphae
48	The thick walled resting spores of fungi is called .....	Blastospores	Arthrospores	Chlamydospores	Zoospores	Chlamydospores
49	The basidiospores are formed on a base known as .....	Sporangium	Basidium	Conidium	Ascus	Basidium
50	The fungi whose sexual phase is not identified is .....	Phycomycetes	Ascomycetes	Basidiomycetes	Deuteromycetes	Deuteromycetes
51	Most fungi of medical importance belong to which group of fungus?	Yeasts	Ascomycetes	Basidiomycetes	Deuteromycetes	Deuteromycetes
52	Generally wet mount of fungal specimens are done after treatment with .....	10% KOH	20% KOH	10% NaOH	20% NaOH	10% KOH
53	Aflatoxin is produced by .....	Penicillium Sp	Rhizopus Sp	Aspergillus flavus	Mucor Sp	Aspergillus flavus
54	Aflatoxin is frequently present in .....	Groundnuts	Flour	Rice	Vegetables	Groundnuts
55	Ergotism is due to toxic effect of .....	Alkaloid	Terpenoid	Phenol	Toxin	Alkaloid
56	Antifungal agents inhibit .....	DNA Synthesis	Fungal protein synthesis	Synthesis of glucan and mannan	Cell Wall Synthesis	Fungal protein synthesis
57	The ..... stains are valuable methods for demonstration of fungal elements in tissue sections.	Periodic acid schiff stain	Grams stain	Malchite green stain	Fast green and silver nitrate	Periodic acid schiff stain
58	The commonest culture	Sabouraud's	Nutrient Agar	Mac Conkey Agar	EMB Agar	Sabouraud's

	media used in mycology include .....	Dextrose agar				Dextrose agar
59	The addition of antibiotics in fungal culture medium prevent .....contamination.	Bacteria	Virus	Algae	Actinomycetes	Bacteria
60	Fungal cultures are incubated at a temperature of ..... for weeks	20 °C	22 °C	23 °C	25 °C	22 °C

**UNIT-II**  
**SYLLABUS**

Superficial mycosis - Cutaneous mycosis - Systemic mycosis - Opportunistic mycosis - Subcutaneous mycosis

**SUPERFICIAL MYCOSES**

**Pityriasis Versicolor**

Pityriasis versicolor is a chronic mild superficial infection of the stratum corneum caused by *Malassezia globosa*, *Malassezia restricta*, and other members of the *Malassezia furfur* complex. Invasion of the cornified skin and the host responses are both minimal. Discrete, serpentine, hyper-, or hypopigmented maculae occur on the skin, usually on the chest, upper back, arms, or abdomen. The lesions are chronic and occur as macular patches of discolored skin that may enlarge and coalesce, but scaling, inflammation, and irritation are minimal. Indeed, this common affliction is largely a cosmetic problem.

*Malassezia* species are lipophilic yeasts, and most require lipid in the medium for growth. The diagnosis is confirmed by direct microscopic examination of scrapings of infected skin, treated with 10–20% potassium hydroxide (KOH) or stained with calcofluor white. Short unbranched hyphae and spherical cells are observed. The lesions also fluoresce under Wood's lamp. Pityriasis versicolor is treated with daily applications of selenium sulfide. Topical or oral azoles are also effective. Rarely, *Malassezia* may cause an opportunistic fungemia in patients—usually infants—receiving total parenteral nutrition, as a result of contamination of the lipid emulsion.

In most cases, the fungemia is transient and corrected by replacing the fluid and intravenous catheter. Some individuals develop folliculitis due to *Malassezia*. Species of *Malassezia* are considered part of the cutaneous microbiota and can be isolated from normal skin and scalp. They have been implicated as a cause of or contributor to seborrheic dermatitis, or dandruff. This hypothesis is supported by the observation that many cases are alleviated by treatment with ketoconazole.

**Tinea nigra**

Tinea nigra (or tinea nigra palmaris) is a superficial chronic and asymptomatic infection of the stratum corneum caused by the dematiaceous fungus *Hortaea (Exophiala) werneckii*. This condition is more prevalent in warm coastal regions and among young women. The lesions appear as a dark (brown to black) discoloration, often on the palm. Microscopic examination of skin scrapings from the periphery of the lesion will reveal branched, septate hyphae and budding yeast cells with melanized cell walls. Tinea nigra will respond to treatment with keratolytic solutions, salicylic acid, or azole antifungal drugs.

**Piedra**

Black piedra is a nodular infection of the hair shaft caused by *Piedraia hortae*. White piedra, due to infection with *Trichosporon* species, presents as larger, softer, yellowish nodules on the hairs. Axillary, pubic, beard, and scalp hair may be infected. Treatment for both types consists of removal of the infected hair and application of a topical antifungal agent. Piedra is endemic in tropical countries.

**CUTANEOUS MYCOSES**

**Dermatophytosis**

Cutaneous mycoses are caused by fungi that infect only the keratinized tissue (skin, hair, and nails). The most important of these are the dermatophytes, a group of about 40 related fungi that belong to three genera: *Microsporum*, *Trichophyton*, and *Epidermophyton*. Dermatophytes are probably restricted to the nonviable skin because most are unable to grow at 37°C or in the presence of serum. Dermatophytoses are among the most prevalent infections in the world. Although they can be persistent and troublesome, they are not debilitating or life-threatening—yet billions of dollars are expended annually in their

treatment. Being superficial, dermatophyte (ringworm) infections have been recognized since antiquity. In skin they

are diagnosed by the presence of hyaline, septate, branching hyphae or chains of arthroconidia. In culture, the many species are closely related and often difficult to identify. They are speciated on the basis of subtle differences in the appearance of the colonies and microscopic morphology as well as a few vitamin requirements. Despite their similarities in morphology, nutritional requirements, surface antigens, and other features, many species have developed various keratinases, elastases, and other enzymes that enable them to be quite host-specific. The identification of closely related and outbreak strains has been greatly aided by DNA sequence analysis. For some species of dermatophytes, a sexual reproductive state has been discovered, and all dermatophytes with a sexual form produce ascospores and belong to the teleomorphic genus *Arthroderma*. Dermatophytes are classified as geophilic, zoophilic, or anthropophilic depending on whether their usual habitat is soil, animals, or humans. Several dermatophytes that normally reside in soil or are associated with particular animal species are still able to cause human infections.

In general, as a species evolves from habitation in soil to a specific animal or human host, it loses the ability to produce asexual conidia and to reproduce sexually. Anthropophilic species cause the greatest number of human infections. They elicit relatively mild and chronic infections, produce few conidia in culture, and may be difficult to eradicate. Conversely, geophilic and zoophilic dermatophytes, being less adapted to human hosts, produce more acute inflammatory infections that tend to resolve more quickly. Dermatophytes are acquired by contact with contaminated soil or with infected animals or humans. Some anthropophilic species are geographically restricted, but others, such as *Epidermophyton floccosum*, *Trichophyton mentagrophytes* var *interdigitale*, *Trichophyton rubrum*, and *Trichophyton tonsurans*, are globally distributed. The most common geophilic species causing human infections is *Microsporum gypseum*. Cosmopolitan zoophilic species (and their natural hosts) include *Microsporum canis* (dogs and cats), *Microsporum gallinae* (fowl), *Microsporum nanum* (pigs), *Trichophyton equinum* (horses), and *Trichophyton verrucosum* (cattle).

### **Morphology and Identification**

The more common dermatophytes are identified by their colonial appearance and microscopic morphology after growth for 2 weeks at 25°C on Sabouraud's dextrose agar. *Trichophyton* species, which may infect hair, skin, or nails, develop cylindric, smooth-walled macroconidia and characteristic microconidia. Depending on the variety, colonies of *T. mentagrophytes* may be cottony to granular; both types display abundant grape-like clusters of spherical microconidia on terminal branches. Coiled or spiral hyphae are commonly found in primary isolates. The typical colony of *T. rubrum* has a white, cottony surface and a deep red, nondiffusible pigment when viewed from the reverse side of the colony. The microconidia are small and piriform (pear-shaped). *Trichophyton tonsurans* produces a flat, powdery to velvety colony on the obverse surface that becomes reddish-brown on reverse; the microconidia are mostly elongate. *Microsporum* species tend to produce distinctive multicellular macroconidia with echinulate walls (Figure 45-10B). Both types of conidia are borne singly in these genera. *Microsporum canis* forms a colony with a white cottony surface and a deep yellow color on reverse; the thick-walled, 8- to 15-celled macroconidia frequently have curved or hooked tips. *Microsporum gypseum* produces a tan, powdery colony and abundant thinwalled, four- to six-celled macroconidia. *Microsporum* species infect only hair and skin.

*Epidermophyton floccosum*, which is the only pathogen in this genus, produces only macroconidia, which are smooth-walled, clavate, two- to four-celled, and formed in small clusters. The colonies are usually flat and velvety with a tan to olive-green tinge. *Epidermophyton floccosum* infects the skin and nails but not the hair. In addition to gross and microscopic morphology, a few nutritional or other tests, such as

growth at 37°C or a test for in vitro hair perforation, are useful in differentiating certain species. Atypical isolates can usually be identified by species-specific polymerase chain reaction (PCR) tests.

### **Epidemiology and Immunity**

Dermatophyte infections begin in the skin after trauma and contact. There is evidence that host susceptibility may be enhanced by moisture, warmth, specific skin chemistry, composition of sebum and perspiration, youth, heavy exposure, and genetic predisposition. The incidence is higher in hot, humid climates and under crowded living conditions. Shoes provide warmth and moisture, a setting for infections of the feet. The source of infection is soil or an infected animal in the case of geophilic and zoophilic dermatophytes, respectively. Anthropophilic species may be transmitted by direct contact or through fomites, such as contaminated towels, clothing, shared shower stalls, and similar examples. Unlike other fungal infections, dermatophytes are contagious and frequently transmitted by exposure to shed skin scales, nails, or hair containing hyphae or conidia. These fungal elements can remain viable for long periods on fomites.

**Trichophytin** is a crude antigen preparation that can be used to detect immediate- or delayed-type hypersensitivity to dermatophytic antigens. Many patients who develop chronic, noninflammatory dermatophyte infections have poor cell-mediated immune responses to dermatophyte antigen. These patients often are atopic and have immediate-type hypersensitivity and elevated IgE concentrations. In the normal host, immunity to dermatophytosis varies in duration and degree depending on the host, the site, and the species of fungus causing the infection.

### **Clinical Findings**

Dermatophyte infections were mistakenly described as ringworm or tinea because of the raised circular lesions, and tradition has maintained this terminology. The clinical forms are based on the site of involvement. A single species is able to cause more than one type of clinical infection. Conversely, a single clinical form, such as tinea corporis, may be caused by more than one dermatophyte species. Table 45-2 lists the more prevalent etiologies of common clinical forms. Very rarely, immunocompromised patients may develop systemic infection by a dermatophyte.

#### **A. Tinea pedis (Athlete's Foot)**

Tinea pedis is the most prevalent of all dermatophytoses. It usually occurs as a chronic infection of the toe webs. Other varieties are the vesicular, ulcerative, and moccasin types, with hyperkeratosis of the sole. Initially, there is itching between the toes and the development of small vesicles that rupture and discharge a thin fluid. The skin of the toe webs becomes macerated and peels, whereupon cracks appear that are prone to develop secondary bacterial infection. When the fungal infection becomes chronic, peeling and cracking of the skin are the principal manifestations, accompanied by pain and pruritus.

#### **B. Tinea unguium (Onychomycosis)**

Nail infection may follow prolonged tinea pedis. With hyphal invasion, the nails become yellow, brittle, thickened, and crumbly. One or more nails of the feet or hands may be involved.

#### **C. Tinea corporis, Tinea cruris, and Tinea manus**

Dermatophytosis of the glabrous skin commonly gives rise to the annular lesions of ringworm, with a clearing, scaly center surrounded by a red advancing border that may be dry or vesicular. The dermatophyte grows only within dead, keratinized tissue, but fungal metabolites, enzymes, and antigens diffuse through the viable layers of the epidermis to cause erythema, vesicle formation, and pruritus. Infections with geophilic and zoophilic dermatophytes produce more irritants and are more inflammatory than anthropophilic species.

As hyphae age, they often form chains of arthroconidia. The lesions expand centrifugally and active hyphal growth is at the periphery, which is the most likely region from which to obtain material for diagnosis. Penetration into the newly forming stratum corneum of the thicker plantar and palmar surfaces



accounts for the persistent infections at those sites. When the infection occurs in the groin area, it is called tinea cruris, or jock itch. Most such infections involve males and present as dry, itchy lesions that often start on the scrotum and spread to the groin. Tinea manus refers to ringworm of the hands or fingers. Dry scaly lesions may involve one or both hands, single fingers, or two or more fingers.

#### **D. Tinea capitis and Tinea barbae**

Tinea capitis is dermatophytosis or ringworm of the scalp and hair. The infection begins with hyphal invasion of the skin of the scalp, with subsequent spread down the keratinized wall of the hair follicle. Infection of the hair takes place just above the hair root. The hyphae grow downward on the nonliving portion of the hair and at the same rate as the hair grows upward. The infection produces dull gray, circular patches of alopecia, scaling, and itching. As the hair grows out of the follicle, the hyphae of *Microsporum* species produce a chain of spores that form a sheath around the hair shaft (ectothrix). These spores impart a

greenish to silvery fluorescence when the hairs are examined under Wood's light (365 nm). In contrast, *T tonsurans*, the chief cause of "black dot" tinea capitis, produces spores within the hair shaft (endothrix). These hairs do not fluoresce; they are weakened and typically break easily at the follicular opening. In prepubescent children, epidemic tinea capitis is usually self-limiting.

Zoophilic species may induce a severe combined inflammatory and hypersensitivity reaction called a **kerion**. Another manifestation of tinea capitis is favus, an acute inflammatory infection of the hair follicle caused by *T schoenleinii*, which leads to the formation of scutula (crusts) around the follicle. In favic hairs, the hyphae do not form spores but can be found within the hair shaft. Tinea barbae involves the bearded region. Especially when a zoophilic dermatophyte is involved, a highly inflammatory reaction may be elicited that closely resembles pyogenic infection.

#### **E. Trichophytid Reaction**

In the course of dermatophytosis, the patient may become hypersensitive to constituents or products of the fungus and develop allergic manifestations—called dermatophytids (usually vesicles)—elsewhere on the body, most often on the hands. The trichophytin skin test is markedly positive in such persons.

#### **Diagnostic Laboratory Tests**

##### **A. Specimens**

Specimens consist of scrapings from both the skin and the nails plus hairs plucked from involved areas. The ectothrixspores of *Microsporum*-infected hairs fluoresce under Wood's light in a darkened room.

##### **B. Microscopic Examination**

Specimens are placed on a slide in a drop of 10–20% potassium hydroxide, with or without calcofluor white, which is a nonspecific fungal cell wall stain that can be viewed with a fluorescent microscope. A coverslip is added, and the specimen is examined immediately and again after 20 minutes. In skin or nails, regardless of the infecting species, branching hyphae or chains of arthroconidia (arthrospores) are seen (Figure 45-11). In hairs, most *Microsporum* species form dense sheaths of spores around the hair (ectothrix). *Trichophyton tonsurans* and *T violaceum* are noted for producing arthroconidia inside the hair shaft (endothrix).

##### **C. Culture**

The identification of dermatophyte species requires cultures. Specimens are inoculated onto inhibitory mold agar or Sabouraud's agar slants containing cycloheximide and chloramphenicol to suppress mold and bacterial growth, incubated for 1–3 weeks at room temperature, and further examined in slide cultures if necessary. Species are identified on the basis of colonial morphology (growth rate, surface texture, and any pigmentation), microscopic morphology (macroconidia, microconidia), and, in some cases, nutritional requirements.

### **Treatment**

Therapy consists of thorough removal of infected and dead epithelial structures and application of a topical antifungal chemical or antibiotic. To prevent reinfection the area should be kept dry, and sources of infection, such as an infected pet or shared bathing facilities, should be avoided.

#### **A. Tinea capitis**

Scalp infections are treated for several weeks with oral administration of griseofulvin or terbinafine. Frequent shampoos and miconazole cream or other topical antifungal agents may be effective if used for weeks. Alternatively, ketoconazole and itraconazole are quite effective.

#### **B. Tinea corporis, Tinea pedis, and Related Infections**

The most effective drugs are itraconazole and terbinafine. However, a number of topical preparations may be used, such as miconazole nitrate, tolnaftate, and clotrimazole. If applied for at least 2–4 weeks, the cure rates are usually 70–100%. Treatment should be continued for 1–2 weeks after clearing of the lesions. For troublesome cases, a short course of oral griseofulvin can be administered.

#### **C. Tinea unguium**

Nail infections are the most difficult to treat, often requiring months of oral itraconazole or terbinafine as well as surgical removal of the nail. Relapses are common.

### **OPPORTUNISTIC MYCOSES**

Patients with compromised host defenses are susceptible to ubiquitous fungi to which healthy people are exposed but usually resistant. In many cases, the type of fungus and the natural history of the mycotic infection are determined by the underlying predisposing condition of the host. As members of the normal mammalian microbiota, *Candida* and related yeasts are endogenous opportunists. Other opportunistic mycoses are caused by exogenous fungi that are globally present in soil, water, and air. The coverage here will focus on the more common pathogens and the diseases they cause—candidiasis, cryptococcosis, aspergillosis, mucormycosis, *Pneumocystis pneumonia*, and penicilliosis.

However, the incidence and the roster of fungal species causing serious mycotic infections in compromised individuals continue to increase. In patients with HIV/AIDS, the susceptibility and incidence of opportunistic mycoses are inversely correlated with the CD4<sup>+</sup> lymphocyte count. In general, AIDS patients with CD4<sup>+</sup> counts less than 200 cells/ $\mu$ L are highly susceptible to infection with opportunistic fungi.

### **CANDIDIASIS**

Several species of the yeast genus *Candida* are capable of causing candidiasis. They are members of the normal flora of the skin, mucous membranes, and gastrointestinal tract. *Candida* species colonize the mucosal surfaces of all humans soon after birth, and the risk of endogenous infection is ever present. Candidiasis is the most prevalent systemic mycosis, and the most common agents are *C. albicans*, *C. parapsilosis*, *C. glabrata*, *C. tropicalis*, *C. guilliermondii*, and *C. dubliniensis*. The widespread use of fluconazole has precipitated the emergence of more azole-resistant species, such as *C. krusei* and *C. lusitanae*. As indicated in Table 45-1, species of *Candida* cause both cutaneous and systemic infections, and these clinical manifestations have different mechanisms of pathogenesis. In addition, there are several other types of candidal infectious syndromes.

#### **Morphology and Identification**

In culture or tissue, *Candida* species grow as oval, budding yeast cells (3–6  $\mu$ m in size). They also form **pseudohyphae** when the buds continue to grow but fail to detach, producing chains of elongated cells that are pinched or constricted at the septations between cells. Unlike other species of *Candida*, *C. albicans* is dimorphic; in addition to yeasts and pseudohyphae, it can also produce true hyphae. On agar

media or within 24 hours at 37°C or room temperature, *Candida* species produce soft, cream-colored colonies with a yeasty odor. Pseudohyphae are apparent as submerged growth below the agar surface. Two simple morphologic tests distinguish *C. albicans*, the most common pathogen, from other species of *Candida*: After incubation in serum for about 90 minutes at 37°C, yeast cells of *C. albicans* will begin to form true hyphae or germ tubes (Figure 45-23), and on nutritionally deficient media *C. albicans* produces large, spherical chlamydospores. Sugar fermentation and assimilation tests can be used to confirm the identification and speciate the more common *Candida* isolates, such as *C. tropicalis*, *C. parapsilosis*, *C. guilliermondii*, *C. kefyr*, *C. krusei*, and *C. lusitaniae*; *C. glabrata* is unique among these pathogens because it produces only yeast cells and no pseudohyphal forms.

### **Antigenic Structure**

The use of adsorbed antisera have defined two serotypes of *C. albicans*: A (which includes *C. tropicalis*) and B. During infection, cell wall components, such as mannans, glucans, other polysaccharides and glycoproteins, as well as enzymes, defenses and Th1 and Th2 immune responses. For example, sera from patients with systemic candidiasis often contain detectable antibodies to candidal enolase, secretory proteases and heat shock proteins.

### **Pathogenesis and Pathology**

Superficial (cutaneous or mucosal) candidiasis is established by an increase in the local census of *Candida* and damage to the skin or epithelium that permits local invasion by the yeasts and pseudohyphae. Systemic candidiasis occurs when *Candida* enters the bloodstream and the phagocytic host defenses are inadequate to contain the growth and dissemination of the yeasts. From the circulation, *Candida* can infect the kidneys, attach to prosthetic heart valves, or produce candidal infections almost anywhere (eg, arthritis, meningitis, endophthalmitis). The local histology of cutaneous or mucocutaneous lesions is characterized by inflammatory reactions varying from pyogenic abscesses to chronic granulomas. The lesions contain abundant budding yeast cells and pseudohyphae. Large increases of *Candida* in the intestinal tract often follow the administration of oral antibacterial antibiotics, and the yeasts can enter the circulation by crossing the intestinal mucosa.

As mentioned above, *Candida* cells elaborate polysaccharides, proteins, and glycoproteins that not only stimulate host defenses but facilitate the attachment and invasion of host cells. *Candida albicans* and other *Candida* species produce a family of agglutinin-like sequence (ALS) surface glycoproteins, some of which are adhesins that bind host receptors and mediate attachment to epithelial or endothelial cells. The innate host defense mechanisms include pattern recognition receptors (eg, lectins, toll-like receptors, macrophage mannose receptor) that bind to pathogen-associated molecular patterns. A key example is the host cell lectin, dectin-1, which binds to the  $\beta$ -1,3-glucan of *C. albicans* and other fungi to stimulate a robust inflammatory response. This response is characterized by the production of cytokines, especially tumor necrosis factor- $\alpha$ , interferon- $\gamma$ , and granulocyte colony-stimulating factor, which activate anti-fungal effector cells, neutrophils, and monocytes. In addition, the binding of  $\beta$ -glucan to dectin 1 on dendritic cells induces the Th17 lymphocytes, which secrete interleukin-17. Th17 lymphocytes differ from T and B cells. They are activated by innate, usually mucosal defense mechanisms as well as adaptive immune responses.

### **Clinical Findings**

#### **A. Cutaneous and Mucosal Candidiasis**

The risk factors associated with superficial candidiasis include AIDS, pregnancy, diabetes, young or old age, birth control pills, and trauma (burns, maceration of the skin). **Thrush** can occur on the tongue, lips, gums, or palate. It is a patchy to confluent, whitish pseudomembranous lesion composed of epithelial cells, yeasts, and pseudohyphae. Thrush develops in most patients with AIDS. Other risk factors include treatment with corticosteroids or antibiotics, high levels of glucose, and cellular immunodeficiency.

Yeast invasion of the vaginal mucosa leads to **vulvovaginitis**, characterized by irritation, pruritus, and vaginal discharge. This condition is often preceded by factors such as diabetes, pregnancy, or antibacterial drugs that alter the microbial flora, local acidity, or secretions. Other forms of **cutaneous candidiasis** include invasion of the skin. This occurs when the skin is weakened by trauma, burns, or maceration. Intertriginous infection occurs in moist, warm parts of the body such as the axillae, groin, and intergluteal or inframammary folds; it is most common in obese and diabetic individuals. The infected areas become red and moist and may develop vesicles. Interdigital involvement between the fingers follows repeated prolonged immersion in water; it is most common in homemakers, bartenders, cooks, and vegetable and fish handlers. Candidal invasion of the nails and around the nail plate causes **onychomycosis**, a painful, erythematous swelling of the nail fold resembling a pyogenic paronychia, which may eventually destroy the nail.

### **B. Systemic Candidiasis**

Candidemia can be caused by indwelling catheters, surgery, intravenous drug abuse, aspiration, or damage to the skin or gastrointestinal tract. In most patients with normal host defenses, the yeasts are eliminated and candidemia is transient. However, patients with compromised innate phagocytic defenses may develop occult lesions anywhere, especially the kidney, skin (maculonodular lesions), eye, heart, and meninges. Systemic candidiasis is most often associated with chronic administration of corticosteroids or other immunosuppressive agents; with hematologic diseases such as leukemia, lymphoma, and aplastic anemia; or with chronic granulomatous disease. Candidal endocarditis is frequently associated with deposition and growth of the yeasts and pseudohyphae on prosthetic heart valves or vegetations. Kidney infections are usually a systemic manifestation, whereas urinary tract infections are often associated with Foley catheters, diabetes, pregnancy, and antibacterial antibiotics.

### **C. Chronic Mucocutaneous Candidiasis**

Most forms of this rare disease have onset in early childhood, are associated with cellular immunodeficiencies and endocrinopathies, and result in chronic superficial disfiguring infections of any or all areas of skin or mucosa. Many patients with chronic mucocutaneous candidiasis are unable to mount an effective Th17 response to *Candida*.

### **Diagnostic Laboratory Tests**

#### **A. Specimens**

Specimens include swabs and scrapings from superficial lesions, blood, spinal fluid, tissue biopsies, urine, exudates, and material from removed intravenous catheters.

#### **B. Microscopic Examination**

Tissue biopsies, centrifuged spinal fluid, and other specimens may be examined in Gram-stained smears or histopathologic slides for pseudohyphae and budding cells. Skin or nail scrapings are first placed in a drop of 10% KOH and calcofluor white.

#### **C. Culture**

All specimens are cultured on fungal or bacteriologic media at room temperature or at 37°C. Yeast colonies are examined for the presence of pseudohyphae. *Candida albicans* is identified by the production of germ tubes or chlamydospores. Other *Candida* isolates are speciated with a battery of biochemical reactions. The interpretation of positive cultures varies with the specimen. Positive cultures from normally sterile body sites are significant. The diagnostic value of a quantitative urine culture depends on the integrity of the specimen and the yeast census. Contaminated Foley catheters may lead to “false-positive” urine cultures. Positive blood cultures may reflect systemic candidiasis or transient candidemia due to a contaminated intravenous line. Sputum cultures have no value because *Candida* species are part of the oral microbiota. Cultures of skin lesions are confirmatory.

#### **D. Serology**



In general, the currently available serologic tests have limited specificity or sensitivity. Serum antibodies and cell-mediated immunity are demonstrable in most people as a result of lifelong exposure to *Candida*. In systemic candidiasis, antibody titers to various candidal antigens may be elevated, but there are no clear criteria for establishing a diagnosis serologically. The detection of circulating cell wall mannan, using a latex agglutination test or an enzyme immunoassay, is much more specific, but the test lacks sensitivity because many patients are only transiently positive or because they do not develop significant and detectable antigen titers until late in the disease. A serologic test for circulating  $\beta$ -glucan, which is found in the cell walls of many fungal species, is not specific for *Candida*. However, this test can be very helpful when considered with other laboratory and clinical data.

### **Immunity**

The basis of resistance to candidiasis is complex and incompletely understood. Cell-mediated immune responses, especially CD4 cells, are important in controlling mucocutaneous candidiasis, and the neutrophil is probably crucial for resistance to systemic candidiasis.

### **Treatment**

Thrush and other mucocutaneous forms of candidiasis are usually treated with topical nystatin or oral ketoconazole or fluconazole. Systemic candidiasis is treated with amphotericin B, sometimes in conjunction with oral flucytosine, fluconazole, or caspofungin. The clearing of cutaneous lesions is accelerated by eliminating contributing factors such as excessive moisture or antibacterial drugs. Chronic mucocutaneous candidiasis responds well to oral ketoconazole and other azoles, but patients have a genetic cellular immune defect and often require lifelong treatment. It is often difficult to establish an early diagnosis of systemic candidiasis—the clinical signs are not definitive, and cultures are often negative. Furthermore, there is no established prophylactic regimen for patients at risk, though treatment with an azole or with a short course of low-dose amphotericin B is often indicated for febrile or debilitated patients who are immunocompromised and do not respond to antibacterial therapy.

### **Epidemiology and Control**

The most important preventive measure is to avoid disturbing the normal balance of microbiota and intact host defenses. Candidiasis is not communicable, since virtually all persons normally harbor the organism. However, molecular epidemiological studies have documented outbreaks caused by the nosocomial transmission of particular strains to susceptible patients (e.g., leukemics, neonates, ICU patients).

### **CRYPTOCOCCOSIS**

*Cryptococcus neoformans* and *Cryptococcus gattii* are environmental, basidiomycetous yeasts. *Cryptococcus neoformans* occurs worldwide in nature and is isolated readily from dry pigeon feces, as well as trees, soil, and other sites. *Cryptococcus gattii* is less common and typically associated with trees in tropical areas. Both species cause cryptococcosis, which follows inhalation of desiccated yeast cells or possibly the smaller basidiospores. From the lungs, these neurotropic yeasts typically migrate to the central nervous system where they cause meningoencephalitis. However, they also have the capacity to infect many other organs (eg, skin, eyes, prostate). *Cryptococcus neoformans* occurs in immunocompetent persons but more often in patients with HIV/AIDS, hematogenous malignancies, and other immunosuppressive conditions. Cryptococcosis due to *C gattii* is rarer and usually associated with apparently normal hosts. Overall, approximately one million new cases of cryptococcosis occur annually, and the mortality approaches 50%. More than 90% of these infections are caused by *C neoformans*. Although *C gattii* is less prevalent globally, for the past decade, there has been an expanding outbreak of infections with this species in the Pacific Northwest.

### Morphology and Identification

In culture, *Cryptococcus* species produce whitish mucoid colonies within 2–3 days. Microscopically, in culture or clinical material, the spherical budding yeast cells (5–10 µm in diameter) are surrounded by a thick nonstaining capsule. All species of *Cryptococcus*, including several nonpathogenic species, are encapsulated and possess urease. However, *C. neoformans* and *C. gattii* differ from non-pathogenic species by the abilities to grow at 37°C and the production of laccase, a phenol oxidase, which catalyzes the formation of melanin from appropriate phenolic substrates (eg, catecholamines). Both the capsule and laccase are well characterized virulence factors. Clinical isolates are identified by demonstrating the production of laccase or a specific pattern of carbohydrate assimilations. Adsorbed antisera have defined five serotypes (A–D and AD); strains of *C. neoformans* may possess serotype A, D, or AD, and isolates of *C. gattii* may have serotype B or C. In addition to their capsular serotypes, the two species differ in their genotypes, ecology, some biochemical reactions, and clinical manifestations.

Sexual reproduction can be demonstrated in the laboratory, and successful mating results in the production of mycelia and basidiospores; the corresponding teleomorphs of the two varieties are *Filobasidiella neoformans* var *neoformans* (serotypes A and D) and *Filobasidiella neoformans* var *bacillispora* (serotypes B and C).

### Antigenic Structure

The capsular polysaccharides, regardless of serotype, have a similar structure: They are long, unbranched polymers consisting of an α-1,3-linked polymannose backbone with β-linked monomeric branches of xylose and glucuronic acid. During infection, the capsular polysaccharide is solubilised in spinal fluid, serum, or urine and can be detected by an enzyme immunoassay or by the agglutination of latex particles coated with antibody to the polysaccharide. With proper controls, this test is diagnostic of cryptococcosis. Patient antibodies to the capsule can also be measured, but they are not used in diagnosis.

### Pathogenesis

Infection is initiated by inhalation of the yeast cells, which in nature are dry, minimally encapsulated, and easily aerosolized. The primary pulmonary infection may be asymptomatic or may mimic an influenza-like respiratory infection, often resolving spontaneously. In patients who are compromised, the yeasts may multiply and disseminate to other parts of the body but preferentially to the central nervous system, causing cryptococcal meningoencephalitis. Other common sites of dissemination include the skin, adrenals, bone, eye, and prostate gland. The inflammatory reaction is usually minimal or granulomatous.

### Clinical Findings

The major clinical manifestation is chronic meningitis, which can resemble a brain tumor, brain abscess, degenerative central nervous system disease, or any mycobacterial or fungal meningitis. Cerebrospinal fluid pressure and protein may be increased and the cell count elevated, whereas the glucose is normal or low. Patients may complain of headache, neck stiffness, and disorientation. In addition, there may be lesions in skin, lungs, or other organs. The course of cryptococcal meningitis may fluctuate over long periods, but all untreated cases are ultimately fatal. Globally, about 58% of patients with AIDS develop cryptococcal meningitis. The infection is not transmitted from person to person.

### Diagnostic Laboratory Tests

#### A. Specimens, Microscopic Examination, and Culture

Specimens include cerebrospinal fluid, tissue, exudates, sputum, blood, cutaneous scrapings, and urine. Spinal fluid is centrifuged before microscopic examination and culture. For direct microscopy, specimens are often examined in wet mounts, both directly and after mixing with India ink, which delineates the capsule. Colonies develop within a few days on most media at room temperature or 37°C. Media with cycloheximide inhibit *Cryptococcus* and should be avoided. Cultures can be identified by growth at 37°C and detection of urease. Alternatively, on an appropriate diphenolic substrate, the phenol oxidase (or



laccase) of *C neoformans* and *C gattii* produces melanin in the cell walls and colonies develop a brown pigment.

### **B. Serology**

Tests for capsular antigen can be performed on cerebrospinal fluid, serum and urine. The latex slide agglutination test or enzyme immunoassay for cryptococcal antigen is positive in 90% of patients with cryptococcal meningitis. With effective treatment, the antigen titer drops—except in AIDS patients, who often maintain high antigen titers for long periods.

### **Treatment**

Combination therapy of amphotericin B and flucytosine has been considered the standard treatment for cryptococcal meningitis, though the benefit from adding flucytosine remains controversial. Amphotericin B (with or without flucytosine) is curative in non-AIDS most patients. Inadequately treated AIDS patients will almost always relapse when amphotericin B is withdrawn and require suppressive therapy with fluconazole, which offers excellent penetration of the central nervous system.

HIV/AIDS patients treated with highly active antiretroviral therapy (HAART) have a lower incidence of cryptococcosis, and cases have a much better prognosis. Unfortunately, up to a third of HAART-treated AIDS patients with cryptococcal meningitis develop **immune reconstitution inflammatory syndrome (IRIS)**, which greatly exacerbates the illness. The diagnosis, pathogenesis, and management of IRIS are problematic. In addition to causing a paradoxical relapse of cryptococcal disease, IRIS may “unmask” undiagnosed cryptococcosis. IRIS also occurs in AIDS patients with tuberculosis.

### **Epidemiology and Ecology**

Bird droppings (particularly pigeon droppings) enrich for the growth of *C neoformans* and serve as a reservoir of infection. The organism grows luxuriantly in pigeon excreta, but the birds are not infected. In addition to patients with AIDS or hematologic malignancies, patients being maintained on corticosteroids are highly susceptible to cryptococcosis. In sub-Saharan Africa, the epicenter of HIV/AIDS, *C neoformans* is the leading cause of meningitis with an estimated one million new cases and 600,000 deaths per year. The vast majority of global cases of cryptococcosis are caused by *C neoformans* (serotype A). However, the normally tropical species *C gattii* has emerged in the Pacific Northwest, where it has been isolated from several local species of trees, soil, and water. Since 2000, human and veterinary cases have expanded from Vancouver Island to mainland British Columbia, Washington, Oregon, California, and Idaho.

## **ASPERGILLOSIS**

Aspergillosis is a spectrum of diseases that may be caused by a number of *Aspergillus* species. *Aspergillus* species are ubiquitous saprobes in nature, and aspergillosis occurs worldwide. *A fumigatus* is the most common human pathogen, but many others, including *A flavus*, *A niger*, *A terreus*, and *A lentulus* may cause disease. This mold produces abundant small conidia that are easily aerosolized. Following inhalation of these conidia, atopic individuals often develop severe allergic reactions to the conidial antigens. In immunocompromised patients—especially those with leukemia, stem cell transplant patients, and individuals taking corticosteroids—the conidia may germinate to produce hyphae that invade the lungs and other tissues.

### **Morphology and Identification**

*Aspergillus* species grow rapidly, producing aerial hyphae that bear characteristic conidial structures: long conidiophores with terminal vesicles on which phialides produce basipetal chains of conidia. The species are identified according to morphologic differences in these structures, including the size, shape, texture, and color of the conidia.

### **Pathogenesis**

In the lungs, alveolar macrophages are able to engulf and destroy the conidia. However, macrophages from corticosteroid- treated animals or immunocompromised patients have a diminished ability to contain the inoculum. In the lung, conidia swell and germinate to produce hyphae that have a tendency to invade preexisting cavities (aspergilloma or fungus ball) or blood vessels.

### **Clinical Findings**

#### **A. Allergic Forms**

In some atopic individuals, development of IgE antibodies to the surface antigens of *Aspergillus* conidia elicits an immediate asthmatic reaction upon subsequent exposure. In others, the conidia germinate and hyphae colonize the bronchial tree without invading the lung parenchyma. This phenomenon is characteristic of **allergic bronchopulmonary aspergillosis**, which is clinically defined as asthma, recurrent chest infiltrates, eosinophilia, and both type I (immediate) and type III (Arthus) skin test hypersensitivity to *Aspergillus* antigen. Many patients produce sputum with *Aspergillus* and serum precipitins. They have difficulty breathing and may develop permanent lung scarring. Normal hosts exposed to massive doses of conidia can develop **extrinsic allergic alveolitis**.

#### **B. Aspergilloma and Extrapulmonary Colonization**

Aspergilloma occurs when inhaled conidia enter an existing cavity, germinate, and produce abundant hyphae in the abnormal pulmonary space. Patients with previous cavitary disease (eg, tuberculosis, sarcoidosis, emphysema) are at risk. Some patients are asymptomatic; others develop cough, dyspnea, weight loss, fatigue, and hemoptysis. Cases of aspergilloma rarely become invasive. Localized, noninvasive infections (colonization) by *Aspergillus* species may involve the nasal sinuses, the ear canal, the cornea, or the nails.

#### **C. Invasive Aspergillosis**

Following inhalation and germination of the conidia, invasive disease develops as an acute pneumonic process with or without dissemination. Patients at risk are those with lymphocytic or myelogenous leukemia and lymphoma, stem cell transplant recipients, and especially individuals taking corticosteroids. The risk is much greater for patients receiving allogeneic (rather than autologous) hematopoietic stem cell

transplants. In addition, AIDS patients with CD4 cell counts less than 50 CD4 cells/ $\mu$ L are predisposed to invasive aspergillosis. Symptoms include fever, cough, dyspnea, and hemoptysis. Hyphae invade the lumens and walls of blood vessels, causing thrombosis, infarction, and necrosis. From the lungs, the disease may spread to the gastrointestinal tract, kidney, liver, brain, or other organs, producing abscesses and necrotic lesions. Without rapid treatment, the prognosis for patients with invasive aspergillosis is grave. Persons with less compromising underlying disease may develop chronic necrotizing pulmonary aspergillosis, which is a milder disease.

### **Diagnostic Laboratory Tests**

#### **A. Specimens, Microscopic Examination, and Culture**

Sputum, other respiratory tract specimens, and lung biopsy tissue provide good specimens. Blood samples are rarely positive. On direct examination of sputum with KOH or calcofluor white or in histologic sections, the hyphae of *Aspergillus* species are hyaline, septate, and uniform in width (about 4  $\mu$ m) and branch dichotomously. *Aspergillus* species grow within a few days on most media morphology of their conidial structures.

#### **B. Serology**

The ID test for precipitins to *A. fumigatus* is positive in over 80% of patients with aspergilloma or allergic forms of aspergillosis, but antibody tests are not helpful in the diagnosis of invasive aspergillosis. For the latter, the serologic test for circulating cell wall galactomannan is diagnostic, although not entirely

specific, for aspergillosis. In addition to testing for circulating galactomannan, the detection of  $\beta$ -glucan is also helpful in diagnosing invasive aspergillosis as well as candidiasis.

### **Treatment**

Aspergilloma is treated with itraconazole or amphotericin B and surgery. Invasive aspergillosis requires rapid administration of either the native or lipid formulation of amphotericin B or voriconazole, often supplemented with cytokine immunotherapy (eg, granulocyte-macrophage colony-stimulating factor or interferon  $\gamma$ ). Amphotericin B-resistant strains of *A terreus* and other species, including *A flavus* and *A lentulus*, have emerged at several leukemia treatment centers, and the new triazole, posaconazole, may be more effective for these infections. The less severe chronic necrotizing pulmonary disease may be treatable with voriconazole or itraconazole. Allergic forms of aspergillosis are treated with corticosteroids or disodium cromoglycate.

### **Epidemiology and Control**

For persons at risk for allergic disease or invasive aspergillosis, efforts are made to avoid exposure to the conidia of *Aspergillus* species. Most bone marrow transplant units employ filtered air-conditioning systems, monitor airborne contaminants in patients' rooms, reduce visiting, and institute other measures to isolate patients and minimize their risk of exposure to the conidia of *Aspergillus* and other molds. Some patients at risk for invasive aspergillosis are given prophylactic low-dose amphotericin B or itraconazole.

## **SUBCUTANEOUS MYCOSES**

The fungi that cause subcutaneous mycoses normally reside in soil or on vegetation. They enter the skin or subcutaneous tissue by traumatic inoculation with contaminated material. For example, a superficial cut or abrasion may introduce an environmental mold with the ability to infect the exposed dermis. In general, the lesions become granulomatous and expand slowly from the area of implantation. Extension via the lymphatics draining the lesion is slow except in sporotrichosis. These mycoses are usually confined to the subcutaneous tissues, but in rare cases they become systemic and produce life-threatening disease.

## **SPOROTRICHOSIS**

*Sporothrix schenckii* is a thermally dimorphic fungus that lives on vegetation. It is associated with a variety of plants—grasses, trees, sphagnum moss, rose bushes, and other horticultural plants. At ambient temperatures, it grows as a mold, producing branching, septate hyphae and conidia, and in tissue or in vitro at 35–37°C as a small budding yeast. Following traumatic introduction into the skin, *S. schenckii* causes **sporotrichosis**, a chronic granulomatous infection. The initial episode is typically followed by secondary spread with involvement of the draining lymphatics and lymph nodes.

### **Morphology and Identification**

*Sporothrix schenckii* grows well on routine agar media, and at room temperature the young colonies are blackish and shiny, becoming wrinkled and fuzzy with age. Strains vary in pigmentation from shades of black and gray to whitish. The organism produces branching, septate hyphae and distinctive small (3–5  $\mu$ m) conidia, delicately clustered at the ends of tapering conidiophores. Isolates may also form larger conidia directly from the hyphae. *Sporothrix schenckii* is thermally dimorphic, and at 35°C on a rich medium it converts to growth as small, often multiply budding yeast cells that are variable in shape but often fusiform (about 1–3  $\times$  3–10  $\mu$ m).

### **Antigenic Structure**

Heat-killed saline suspensions of cultures or carbohydrate fractions (**sporotrichin**) will elicit positive delayed skin tests in infected humans or animals. A variety of serologic tests have been developed, and most patients, as well as some normal individuals, have specific or cross-reactive antibodies.

### **Pathogenesis and Clinical Findings**

The conidia or hyphal fragments of *S. schenckii* are introduced into the skin by trauma. Patients frequently recall a history of trauma associated with outdoor activities and plants. The initial lesion is usually located on the extremities but can be found anywhere (children often present with facial lesions). About 75% of cases are lymphocutaneous; that is, the initial lesion develops as a granulomatous nodule that may progress to form a necrotic or ulcerative lesion. Meanwhile, the draining lymphatics become thickened and cord-like. Multiple subcutaneous nodules and abscesses occur along the lymphatics.

Fixed sporotrichosis is a single nonlymphangitic nodule that is limited and less progressive. The fixed lesion is more common in endemic areas such as Mexico, where there is a high level of exposure and immunity in the population. Immunity limits the local spread of the infection. There is usually little systemic illness associated with these lesions, but dissemination may occur, especially in debilitated patients. Rarely, primary pulmonary sporotrichosis results from inhalation of the conidia. This manifestation mimics chronic cavitary tuberculosis and tends to occur in patients with impaired cell-mediated immunity.

### **Diagnostic Laboratory Tests**

#### **A. Specimens**

Specimens include biopsy material or exudate from granulomatous or ulcerative lesions.

#### **B. Microscopic Examination**

Although specimens can be examined directly with KOH or calcofluor white stain, the yeasts are rarely found. Even though they are sparse in tissue, the sensitivity of histopathologic sections is enhanced with routine fungal cell wall stains, such as Gomori methenamine silver, which stains the cell walls black, or the periodic acid-Schiff stain, which imparts a red color to the cell walls. Alternatively, they can be identified by fluorescent antibody staining. The yeasts are 3–5  $\mu\text{m}$  in diameter and spherical to elongated. Another structure termed an asteroid body is often seen in tissue, particularly in endemic areas such as Mexico, South Africa, and Japan. In hematoxylin and eosin-stained tissue, the asteroid body consists of a central basophilic yeast cell surrounded by radiating extensions of eosinophilic material, which are depositions of antigen–antibody complexes and complement.

#### **C. Culture**

The most reliable method of diagnosis is culture. Specimens are streaked on inhibitory mold agar or Sabouraud's agar containing antibacterial antibiotics and incubated at 25–30°C. The identification is confirmed by growth at 35°C and conversion to the yeast form.

#### **D. Serology**

High titers of agglutinating antibodies to yeast cell suspensions or antigen-coated latex particles are often detected in sera of infected patients. However, these tests are generally not useful because elevated titers do not develop early in the course of disease and uninfected or previously exposed patients may give false-positive results.

### **Treatment**

In some cases, the infection is self-limited. Although the oral administration of saturated solution of potassium iodide in milk is quite effective, it is difficult for many patients to tolerate. The treatment of choice is oral itraconazole or another azole. For systemic disease, amphotericin B is given.



### **Epidemiology and Control**

*Sporothrix schenckii* occurs worldwide in close association with plants. For example, cases have been linked to contact with sphagnum moss, rose thorns, decaying wood, pine straw, prairie grass, and other vegetation. About 75% of cases occur in males, either because of increased exposure or because of an X-linked difference in susceptibility. The incidence is higher among agricultural workers, and sporotrichosis

is considered an occupational risk for forest rangers, horticulturists, and workers in similar occupations. Prevention includes measures to minimize accidental inoculation and the use of fungicides, where appropriate, to treat wood. Animals are also susceptible to sporotrichosis.

### **CHROMOBLASTOMYCOSIS**

Chromoblastomycosis (chromomycosis) is a subcutaneous mycotic infection that is usually caused by traumatic inoculation of any of the recognized fungal agents, which reside in soil and vegetation. All are dematiaceous fungi, having melanized cell walls: *Phialophora verrucosa*, *Fonsecaea pedrosoi*, *Fonsecaea compacta*, *Rhinocladiella aquaspersa*, and *Cladophialophora carrionii*. The infection is chronic and characterized by the slow development of progressive granulomatous lesions that in time induce hyperplasia of the epidermal tissue.

#### **Morphology and Identification**

The dematiaceous fungi are similar in their pigmentation, antigenic structure, morphology, and physiologic properties. The colonies are compact, deep brown to black, and develop a velvety, often wrinkled surface. The agents of chromoblastomycosis are identified by their modes of conidiation. In tissue they appear the same, producing spherical brown cells (4–12 µm in diameter) termed muriform or sclerotic bodies that divide by transverse septation. Septation in different planes with delayed separation may give rise to a cluster of four to eight cells. Cells within superficial crusts or exudates may germinate into septate, branching hyphae.

##### **A. *Phialophora verrucosa***

The conidia are produced from flask-shaped phialides with cup-shaped collarettes. Mature, spherical to oval conidia are extruded from the phialide and usually accumulate around it.

##### **B. *Fonsecaea pedrosoi***

*Fonsecaea* is a polymorphic genus. Isolates may exhibit (1) phialides; (2) chains of blastoconidia, similar to *Cladosporium* species; or (3) sympodial, rhinocladiella-type conidiation. Most strains of *F. pedrosoi* form short branching chains of blastoconidia as well as sympodial conidia.

##### **C. *Fonsecaea compacta***

The blastoconidia produced by *F. compacta* are almost spherical, with a broad base connecting the conidia. These structures are smaller and more compact than those of *F. pedrosoi*.

##### **D. *Rhinocladiella aquaspersa***

This species produces lateral or terminal conidia from a lengthening conidiogenous cell—a sympodial process. The conidia are elliptical to clavate.

##### **E. *Cladophialophora (Cladosporium) carrionii***

Species of *Cladophialophora* and *Cladosporium* produce branching chains of conidia by distal (acropetalous) budding. The terminal conidium of a chain gives rise to the next conidium by a budding process. Species are identified based on differences in the length of the chains and the shape and size of the conidia. *Cladophialophora carrionii* produces elongated conidiophores with long, branching chains of oval conidia.



### **Pathogenesis and Clinical Findings**

The fungi are introduced into the skin by trauma, often of the exposed legs or feet. Over months to years, the primary lesion becomes verrucous and wart-like with extension along the draining lymphatics. Cauliflower-like nodules with crusting abscesses eventually cover the area. Small ulcerations or “black dots” of hemopurulent material are present on the warty surface. Rarely, elephantiasis may result from secondary infection, obstruction, and fibrosis of lymph channels. Dissemination to other parts of the body is very rare, though satellite lesions can occur due either to local lymphatic spread or to autoinoculation. Histologically, the lesions are granulomatous and the dark sclerotic bodies may be seen within leukocytes or giant cells.

### **Diagnostic Laboratory Tests**

Specimens of scrapings or biopsies from lesions are placed in 10% KOH and examined microscopically for dark, spherical cells. Detection of the sclerotic bodies is diagnostic of chromoblastomycosis regardless of the etiologic agent. Tissue sections reveal granulomas and extensive hyperplasia of the dermal tissue. Specimens should be cultured on inhibitory mold agar or Sabouraud’s agar with antibiotics. The dematiaceous species is identified by its characteristic conidial structures, as described above. There are many similar saprophytic dematiaceous molds, but they differ from the pathogenic species in being unable to grow at 37°C and being able to digest gelatin.

### **Treatment**

Surgical excision with wide margins is the therapy of choice for small lesions. Chemotherapy with flucytosine or itraconazole may be efficacious for larger lesions. The application of local heat is also beneficial. Relapse is common.

### **Epidemiology**

Chromoblastomycosis occurs mainly in the tropics. The fungi are saprophytic in nature, probably occurring on vegetation and in soil. The disease occurs chiefly on the legs of barefoot agrarian workers following traumatic introduction of the fungus. Chromoblastomycosis is not communicable. Wearing shoes and protecting the legs probably would prevent infection.

## **MYCETOMA**

Mycetoma is a chronic subcutaneous infection induced by traumatic inoculation with any of several saprophytic species of fungi or actinomycetous bacteria that are normally found in soil. The clinical features defining mycetoma are local swelling of the infected tissue and interconnecting, often draining, sinuses or fistulae that contain granules, which are microcolonies of the agent embedded in tissue material. An **actinomycetoma** is a mycetoma caused by an actinomycete; a **eumycetoma** (maduromycosis, Madura foot) is a mycetoma caused by a fungus. The natural history and clinical features of both types of mycetoma are similar, but actinomycetomas may be more invasive, spreading from the subcutaneous tissue to the underlying muscle. Of course, the therapy is different. Mycetoma occurs worldwide but more often among impoverished people who reside in tropical areas and wear less protective clothing. Mycetomas occur only sporadically outside the tropics but are particularly prevalent in India, Africa, and Latin America.

### **Morphology and Identification**

The fungal agents of mycetoma include, among others, *Pseudallescheria boydii* (anamorph, *Scedosporium apiospermum*), *Madurella mycetomatis*, *Madurella grisea*, *Exophiala jeanselmei*, and *Acremonium falciforme*. In the United States, the prevalent species is *Pseudallescheria boydii*, which is self-fertile (homothallic) and has the ability to produce ascospores in culture. *Exophiala jeanselmei* and the *Madurella* species are dematiaceous molds. These molds are identified primarily by their mode of

conidiation. *Pseudallescheria boydii* may also cause pseudallescheriasis, which is a systemic infection of compromised patients.

In tissue, the mycetoma granules may range up to 2 mm in size. The color of the granule may provide information about the agent. For example, the granules of mycetoma caused by *Pseudallescheria boydii* and *Acremonium falciforme* are white; those of *Madurella grisea* and *Exophiala jeanselmei* are black; and *Madurella mycetomatis* produces a dark red to black granule. These granules are hard and contain intertwined, septate hyphae (3–5 µm in width). The hyphae are typically distorted and enlarged at the periphery of the granule.

### **Pathogenesis and Clinical Findings**

Mycetoma develops after traumatic inoculation with soil contaminated with one of the agents. Subcutaneous tissues of the feet, lower extremities, hands, and exposed areas are most often involved. Regardless of the agent, the pathology is characterized by suppuration and abscesses, granulomata, and draining sinuses containing the granules. This process may spread to contiguous muscle and bone. Untreated lesions persist for years and extend deeper and peripherally, causing deformation and loss of function. Very rarely, *Pseudallescheria boydii* may disseminate in an immunocompromised host or produces infection of a foreign body (eg, a cardiac pacemaker).

### **Diagnostic Laboratory Tests**

Granules can be dissected out from the pus or biopsy material for examination and culture on appropriate media. The granule color, texture, and size and the presence of hyaline or pigmented hyphae (or bacteria) are helpful in determining the causative agent. Draining mycetomas are often superinfected with staphylococci and streptococci.

### **Treatment**

The management of eumycetoma is difficult, involving surgical debridement or excision and chemotherapy. *Pseudallescheria boydii* is treated with topical nystatin or miconazole. Itraconazole, ketoconazole, and even amphotericin B can be recommended for *Madurella* infections and flucytosine for *Exophiala jeanselmei*. Chemotherapeutic agents must be given for long periods to adequately penetrate these lesions.

### **Epidemiology and Control**

The organisms producing mycetoma occur in soil and on vegetation. Barefoot farm laborers are therefore commonly exposed. Properly cleaning wounds and wearing shoes are reasonable control measures.

---

**Possible Questions**

**Part B (Two marks)**

1. Define superficial mycosis.
2. Define Cutaneous mycosis.
3. Define Systemic mycosis.
4. Define Opportunistic mycosis.
5. Define subcutaneous mycosis.
6. What is Exothrix?
7. What is Endothrix?
8. Write about piedra?

**Part B (Eight marks)**

1. Explain the characteristics of *Pityriasis versicolor*.
2. Explain the pathogenecity of *Pityriasis versicolor*.
3. Laboratory diagnosis of *Pityriasis versicolor*.
4. Explain the characteristics of *Tinea nigra*.
5. Explain the pathogenecity of *Tinea nigra*.
6. Laboratory diagnosis of *Tinea nigra*.
7. Describe briefly about Dermatophytes.
8. Explain the pathogenecity of *Candida albicans*
9. Outline the Laboratory diagnosis and treatment of *Candida albicans*.
10. Write about the morphology and antigenic property of *Cryptococcus neoformans*.
11. Explain the pathogenecity of *Aspergillus niger*.
12. Explain the pathogenecity of *Cladophialophora carrionii*.
13. Write about the morphology and pathogenecity of Actinomycetes.
14. Laboratory diagnosis of *Aspergillosis*.
15. Write about the morphology and pathogenecity of *Sporothrix schenckii*.

	Unit II	Option 1	Option 2	Option 3	Option 4	Answer
1	Each of the following statements concerning <i>Candida albicans</i> is correct except	<i>C. albicans</i> is a budding yeast that forms pseudohyphae when it invades tissue	<i>C. albicans</i> causes thrush	<i>C. albicans</i> is transmitted primarily by respiratory aerosol	Impaired cell mediated immunity is an important predisposing factor to disease	<i>C. albicans</i> is transmitted primarily by respiratory aerosol
2	Ergotism is responsible for all of the following except	hallucinations	Irish potato famine	both (a) and (b)	gangrene	gangrene
3	The basidiomycetes include plant parasites that can cause	rust and smut diseases	candidiasis	ergot disease	Dutch elm disease & chestnut blight	rust and smut diseases
4	Ergots are obtained from	Rhizopus	Claviceps	Albuca	Phytomonas	Claviceps
5	one of the common fungal disease in man	Cholera	Plague	Ringworm	Typhoid	Ringworm
6	Aflatoxin is produced by	Bacteria	Fungi	Virus	Nematode	Fungi
7	Fungi that causes thrush in human is .....	Trichophyton schonlainii	Candida albicans	Puccinia gra	Yeast	Candida albicans
8	Which of the following belong to systemic mycoses .....	Cryptococcosis	Blastomycosis	Histoplasmosis	Coccidiomycosis	Cryptococcosis
9	Cryptococcosis is caused by .....	Bacteria	Virus	Yeast	Parasite	Yeast
10	Cryptococcus neoformans causes .....	Cryptococcosis	Histoplasmosis	Coccidiomycosis	Chromoblastomycosis	Cryptococcosis
11	Cryptococcus consists of .....capsule.	Lignin	Polysaccharide	Cellulose	Chitin	Polysaccharide
12	Cryptococcus is a .....	Soil saprophyte	Soil parasite	Parasite	Saprophyte	Soil saprophyte
13	A girl who pricked her finger while pruning some rose bushes develops a local pustule that	<i>Aspergillus fumigatus</i>	<i>Sporothrix schenckii</i>	<i>Cryptococcus neoformans</i>	<i>Candida albicans</i>	<i>Sporothrix schenckii</i>

	progresses to an ulcer. Several nodules then develop along the local lymphatic drainage. The most likely agent is					
14	Immuno compromised persons are suffered from several fungal diseases. Which of the following is the least frequently associated	<i>Cryptococcus neoformans</i>	<i>Aspergillus fumigatus</i>	<i>Malassezia furfur</i>	Mucor species	<i>Malassezia furfur</i>
15	Each of the following statements concerning <i>Cryptococcus neoformans</i> are correct EXCEPT	Its natural habitat is the soil, especially associated with pigeon feces	Budding yeasts are found in the lesions	The initial site of infection is usually the lung	Pathogenesis is related primarily to the production of exotoxin A.	Pathogenesis is related primarily to the production of exotoxin A.
16	Fungal cells that reproduce by budding are seen in the infected tissues of patients with	Candidiasis, cryptococcosis, and sporotrichosis	Mycetoma, candidiasis and mucormycosis	Tinea corporis, tinea unguium, and tinea versicolor	Sporotrichosis, mycetoma and aspergillosis	Candidiasis, cryptococcosis, and sporotrichosis
17	Which of the following is not the characteristics of histoplasmosis	Person to person transmission	Specific geographic distribution	Yeasts in tissue	mycelial phase in the soil	Person to person transmission
18	Infection with dermatophyte is most often associated with	intravenous drug abus	inhalation of the organism from contaminated bird feces	adherence of the organism to perspiration moist skin	Fecal-oral transmission	adherence of the organism to perspiration moist skin
19	<i>Cryptococcus</i> infection is acquired through .....	Contact	Inhalation	Transmission	Mucor membrane	Inhalation
20	Visceral form of cryptococcal disease lead to .....	Cancer	Tuberculosis	Skin disease	Tuberculosis and Cancer	Tuberculosis and Cancer
21	Histoplasmosis is a .....infection	Extracellular	Intercellular	Intracellular	Superficial	Intracellular
22	In USA, Histoplasmosis is	Endemic	Epidemic	Sporadic	Pendemic	Endemic



	a ..... Disease					
23	The fungus Histoplasma appear ... in sabouraud's agar medium	Green	Red	Pink	White	White
24	African histoplasmosis involves .....	Skin	Subcutaneous tissue	Bones	Cutaneous tissue	Skin
25	Blastomycosis is caused by .....	Bacteria	Yeast	Mold	Dimorphic fungi	Dimorphic fungi
26	Source of infection of Blastomycosis is .....	Soil	Air	Water	Dust	Soil
27	The initial lesion in Blastomycosis is .....	Papilla	Macule	Papule	Scar	Papule
28	Which of the following fungi is most likely to be found within reticuloendothelial cells?	<i>Histoplasma Capsulatum</i>	<i>Sporothrix Schenckii</i>	<i>Cryptococcus neoforman</i>	<i>Candida albicans</i>	<i>Histoplasma Capsulatum</i>
29	Aspergillosis is recognized in tissue by the presence of	Metachromatic granules	Psuedohyphae	Septate hyphae	Budding cells	Septate hyphae
30	Fungi often colonize lesions due to other causes. Which of the following is least likely to be present as colonizer	Candida	Sporothrix	Mucor	Aspergillus	Sporothrix
31	Common laboratory contaminants include ...	Aspergillus	Cryptococcus	Tenia	Candida	Aspergillus
32	The asexual conidia of Aspergillus are arranged on .....	Sterigmata	Sterigma	Stigma	Sigma	Sterigmata
33	Coccidioidomycosis is caused by .....	Mold	Yeast	Dimorphic fungus	Yeast-like fungi	Dimorphic fungus
34	Coccidioidomycosis infection is acquired through .....	Inhalation	Air	Water	Soil	Inhalation
35	In coccidioidomycosis, the dust contain	Conidiospores	Basidiospores	Basidiospores	Arthrospores	Arthrospores

	..... spores of fungus.					
36	Chronic progressive disseminated disease of coccidioides is .....	Coccidioidal granuloma	Glaucoma	Pulmonary Sarcoma	Sarcoma	Glaucoma
37	..... is a geophilic dermatophyte	M.gypseum	M.fulvum	M.nanum	M. restricta	M.gypseum
38	..... is an anthropophilic dermatophyte	T.rubrum	E.floccosum	Tinea pedis	Microsporum	Microsporum
39	..... shows club shaped macroconidia arranged in clusters	M.gypseum	E.Flocosum	T.rurum	T.rubrum	T.rurum
40	..... is a infection caused by dermatophytes	Tinea nigra	Tinea nigra	Tinea versicolor	Tinea imbricate	Tinea nigra
41	..... is dermatophytosis of non-hairy skin	Tinea imbricate	Tinea Corporis	Tinea circinata	Tinea versicolor	Tinea Corporis
42	..... gives bright green fluorescence under wood's lamp	Micosporum	Trichophyton sp	Piedra hortae	P.orbicularae	Micosporum
43	Two types of human fungus infections include .....	Surface and cutaneous infections	Surface and Subcutaneous	Cutaneous and Subcutaneous	Cutaneous and Subcutaneous	Cutaneous and Subcutaneous
44	Ringworm affect .....	Skin	Hair	Skin and hair	Eye	Skin and hair
45	Fungi causing superficial mycoses are .....	Parasites	Saprophytes	Epiphyte	Endophyte	Saprophytes
46	Fungi causing superficial mycoses possess the capacity to digest .....	Keratin	Chitin	Cutin	Protein	Keratin
47	Opportunistic infections are caused by fungi that are .....	Virulent	Avirulent	Both Virulent and Avirulent	Pathogen	Both Virulent and Avirulent
48	Surface infections are	Aspergillus sp	Cryptococcus	Candida albicans	Tinea Piedra	Tinea Piedra

	caused by .....					
49	Candida albicans produces .....	Pseudomycelia	True mycelia	Hypha	Pseudohyphae	Pseudomycelia
50	All Candida strains are sensitive to .....	Neomycin	Amphotericin	Nystatin	Clotrimazole	Nystatin
51	Tinea nigra infection is characterized by	Pale white patches	Black on scalp	Nodules on hair shaft	Black dot on scalp	Black dot on scalp
52	In white piedra, the nodules on the hair shaft are	Dull and pale	dark and dull	Hard and dark	Hard and pale	dark and dull
53	Infection caused by dermatophytes is called as	Dermatophytosis	Tinea infection	Ringworm infection	Candida infection	Dermatophytosis
54	The following are zoophilic dermatophytes except	T.rubrum	M.canis	M.equinum	T.equinum	T.equinum
55	Candida albicans cause .....infections	Surface	Cutaneous	Subcutaneous	Systemic	Cutaneous
56	Tinea nigra produce ..... maculaslesions	Black / Brown	Red / Blue	Brown / Yellow	Green / Yellow	Black / Brown
57	Dermatophytes have been classified into ... genera	Two	Three	Four	Five	Three
58	Trichophyton is classified under .....	Dermatophyte	Superficial mycosis	Deep mycosis	Opportunistic mycosis	Dermatophyte
59	Tinea nigra, a fungal infection of skin is caused by .....	Cladosporium	Piedraia	Trichosporon	Malassezia	Trichosporon
60	Tinea nigra is treated effectively with tincture of .....	Iron	Iodine	Potassium	Magnesium	Iodine

**UNIT-III**  
**SYLLABUS**

Introduction to Parasitology - protozoa-amoebae – flagellates - Laboratory techniques in parasitology - Ova, cyst analysis direct and concentration methods. Blood smear examination - antiprotozoan therapy.

**INTRODUCTION TO PARASITOLOGY**

**Classification of Parasites**

The parasites covered in this chapter are categorized into two major groups: **parasitic protozoa** and **parasitic helminths**. **Protozoa** are unicellular eukaryotes that form an entire kingdom. Classifying protozoan parasites into taxonomic groups is an ongoing process, and their status is often in a state of flux. For this reason, this chapter separates the parasitic protozoa into four traditional groups based on their means of locomotion and mode of reproduction: flagellates, amebae, sporozoa, and ciliates.

(1) **Flagellates** have one or more whiplike flagella and, in some cases, an undulating membrane (eg, trypanosomes). These include intestinal and genitourinary flagellates (*Giardia* and *Trichomonas*, respectively) and blood and tissue flagellates (*Trypanosoma* and *Leishmania*).

(2) **Amebae** is typically ameboid and use pseudopodia or protoplasmic flow to move. They are represented in humans by species of *Entamoeba*, *Naegleria*, and *Acanthamoeba*.

(3) **Sporozoa** undergoes a complex life cycle with alternating sexual and asexual reproductive phases. The human parasites *Cryptosporidium*, *Cyclospora*, and *Toxoplasma* and the malarial parasites (*Plasmodium* species) are all intracellular parasites.

(4) **Ciliates** are complex protozoa bearing cilia distributed in rows or patches, with two kinds of nuclei in each individual. *Balantidium coli*, a giant intestinal ciliate of humans and pigs, is the only human parasite representative of this group, and because the disease is considered rare.

Formerly listed with the sporozoa, because they possess polar filaments within a spore, **microsporidia** include more than 1000 species of intracellular parasites that infect invertebrates (mostly insects) and vertebrate hosts. In humans, microsporidians are opportunistic parasites of immunocompromised patients, including those undergoing chemotherapy and organ transplants. *Pneumocystis carinii* was long considered a protozoan parasite but has been shown to be a member of the fungi rather than the protozoa. It causes interstitial plasma cell pneumonitis in immunosuppressed individuals and is considered an opportunistic pathogen. **Parasitic helminths**, or worms of humans, belong to two phyla: Nematoda (roundworms) and Platyhelminthes (flatworms).

(1) **Nematodes** are among the most speciose and diverse animals. They are elongated and tapered at both ends, round in cross section, and unsegmented. They have only a set of longitudinal muscles, which allows them to move in a whiplike, penetrating fashion; a complete digestive system that is well adapted for ingestion of the host's gut contents, cells, blood, or cellular breakdown products; and a highly developed separate-sexed reproductive system. They shed their tough cuticles (molt) as they undergo development from larvae to adults, and the eggs and larval stages are well suited for survival in the external environment. Most human infections are acquired by ingestion of the egg or larval stage, but nematode infections can also be acquired from insect vectors and skin penetration.

(2) **Platyhelminthes** are flatworms that are dorsoventrally flattened in cross section and are hermaphroditic, with a few exceptions. All medically important species belong to two classes: **Trematoda** (flukes) and **Cestoda** (tapeworms).

**Trematodes** are typically flattened and leaf shaped with two muscular suckers. They have a bifurcated gut and possess both circular and longitudinal muscles; they lack the cuticle characteristic of nematodes and instead have a syncytial epithelium. Trematodes are hermaphroditic, with the exception of the schistosomes

(blood flukes), which have male and female worms that exist coupled together within small blood vessels of their hosts. The life cycle of human trematodes is typically initiated when eggs are passed into fresh water via feces or urine. Eggs develop, hatch, and release a ciliated miracidium, which infects a snail host that is usually highly specific to the fluke species. Within the snail, the miracidium develops into a sporocyst, which contains germinal cells that ultimately develop into the final larval stage—the cercariae. These swim out of the snail and encyst as metacercariae in a second intermediate host or on vegetation, depending on the species. Most fluke infections are acquired by ingestion of the metacercariae. The cercariae of schistosomes, however, directly penetrate the skin of their hosts and do not encyst as metacercariae.

**Cestodes**, or tapeworms, are flat and have a ribbon-like chain of segments (proglottids) containing male and female reproductive structures. Adult tapeworms can reach lengths of 10 m and have hundreds of segments, with each segment releasing thousands of eggs. At the anterior end of an adult tapeworm is the scolex, which is often elaborated with muscular suckers, hooks, or structures that aid in its ability to attach to the intestinal wall. Adult tapeworms have no mouth or gut and absorb their nutrients directly from their host through their integument.

The life cycle of cestodes, like that of the trematodes, is usually indirect (involving one or more intermediate hosts and a final host). Eggs are excreted with the feces and ingested by an intermediate host (invertebrate, such as a flea, or vertebrate, such as a mammal); the larvae develop into certain forms that are peculiar to the specific species within the intermediate host (eg, cysticercus in the case of *Taenia solium* or hydatid cyst with *Echinococcus granulosus*). Cestode larvae are generally eaten, and the larva develops into an adult worm in the intestine of the final host.

### **LABORATORY TECHNIQUES IN PARASITOLOGY**

Laboratory procedures play an important role in the diagnosis of parasitic infections, both for confirmation of clinical suspicion and for identifying unsuspected infections. The principles of laboratory diagnosis are the same as in bacterial and viral infections, but the relative importance of the different methods varies greatly. While isolation of the infecting agent and detection of specific antibodies are the major methods in bacteriology and virology, they are much less important in parasitology than morphological identification of the parasite by microscopy. Compared to bacteria and viruses, parasites are very large and possess distinctive shape and structure which enable their specific diagnosis on morphological grounds. Due to their complex antigenic structure and extensive cross-reactions, serological diagnosis is of limited value in parasitic infections. Though many pathogenic parasites can be grown in laboratory cultures this is not suitable for routine diagnosis because of its relative insensitivity and the delay involved.

Morphological diagnosis of parasites consists of two steps—detection of the parasite or its parts in clinical samples and its identification. Detection depends on collection of the appropriate samples and their examination by suitable techniques. Identification requires adequate skill and expertise in recognising the parasite in its various stages and its differentiation from morphologically similar artefacts. A description of the common diagnostic techniques in parasitology is given below.

### **EXAMINATION OF FECES**

Specimens should be collected in suitable clean containers, avoiding contamination with urine, water or disinfectants. Normally passed stools are preferable, though samples obtained after purgative (sodium sulphate) or high saline enema may also be used. Examination of fresh specimens is necessary for observing motility of protozoan parasites.



Feces should be examined for its consistency, colour, odour and presence of blood or mucus. In some instances, parasites may be seen on gross inspection as in the case of roundworm, pinworm or tapeworm proglottides.

### **Microscopy**

The microscope should be equipped with a micrometer eyepiece, as it is often essential to measure the size of parasites. For example, the differentiation between cysts of the pathogenic *Entamoeba histolytica* and the non-pathogenic *E. hartmanni* is based entirely on their sizes. Microscopy should also include contributory findings such as the presence of Charcot-Leyden crystals and cellular exudate.

For detection of parasites, it is best to employ a combination of methods, as different methods serve different purposes. The methods include examination of wet mounts, thick smears and permanent stained preparations. Various concentration methods can be used to increase the sensitivity of microscopic examination.

### **Wet Mounts**

The unstained wet film is the standard preparation and is made by emulsifying a small quantity of feces in a drop of saline placed on a slide and applying a coverslip on top, avoiding air bubbles. A proper preparation should be just dense enough for newspaper print to be read through it. If the feces contains mucus, it is advisable to prepare films using the mucus part. Wet saline mounts are particularly useful for detecting live motile trophozoites of *E. histolytica*, *B. coli* and *G. lamblia*. Eggs of helminths are also readily seen.

Eosin, 1% aqueous solution can be used for staining wet films. Eosin stains everything except living protoplasm. Trophozoites and cysts of protozoa as well as helminth larvae and thin-walled eggs stand out as pearly white objects against a pink background and can be easily detected. Chromatoid bodies and nuclei of amoebic cysts can be seen prominently. Eosin also indicates the viability of cysts; live cysts are unstained and dead ones stained pink.

Iodine staining of wet mounts is another standard method of examination. Either Lugol's iodine diluted 1 to 5 or Dobell and O'Connor's iodine solution (1g iodine, 2 g potassium iodide, 100 ml distilled water) is used. Iodine helps to confirm the identity of cysts, as it stains prominently the glycogen vacuoles and nuclei.

### **Thick Smears**

These are not useful for routine examination, but are valuable in surveys for intestinal helminth eggs. The method described by Kato and Miura in 1954 is known as the Kato thick smear technique. About 50 mg feces is taken on a slide and covered with a special wettable cellophane coverslip soaked in glycerine containing aqueous malachite green. The preparation is left for about an hour at room temperature, in which period the glycerine clears the feces enabling the helminth eggs to be seen distinctly under low power magnification. This method is however not useful for diagnosis of protozoa or helminth larvae.

### **Permanent Stained Smears**

These are employed for identification of protozoa in feces and also as permanent records. The two methods commonly used are the iron-haematoxylin stain and Wheatley's trichrome stain. The iron-haematoxylin is the older method, but is more difficult.

### **Iron-Haematoxylin Stain**

Fecal smear on a slide is fixed in Schaudinn's solution for 15 minutes and is immersed successively for 2-5 minutes in 70% alcohol, 70% alcohol containing a trace of iodine, 70% and 50% alcohol. It is washed in water for 5-10 minutes and immersed in 2% aqueous ferric ammonium sulphate solution for 5-15 minutes. It is then washed in water for 3-5 minutes and stained with 0.5% aqueous haematoxylin for 5-15 minutes. It is washed for 2-5 minutes and differentiated in saturated aqueous solution of picric acid for 10-15 minutes.

It is then washed for 10-15 minutes and dehydrated by passing through increasing strengths of alcohol, cleared in toluene or xylol and mounted.

### **Wheatley Trichrome Stain**

This is a simpler and quicker method. The smear is fixed in Schaudinn's solution and taken successively through alcohol, as above. Trichrome stain (chromotrope 2 R, light green SF and phosphotungstic acid in glacial acetic acid and distilled water) is then applied for 5-10 minutes, differentiated in acid alcohol for 2-3 seconds, dehydrated, cleared and mounted. Other staining techniques are used for special purpose. For example, modified acid-fast or Giemsa stain is employed for detection of oocysts of cryptosporidium and isospora.

### **Concentration Methods**

When the parasites are scanty in stools, routine microscopic examination may fail to detect them. It is then necessary to selectively concentrate the protozoan cysts and helminth eggs and larvae. Concentration may be done using fresh or preserved feces. Several concentration techniques have been described. They can be classified as the floatation or sedimentation methods. In floatation method, the feces is suspended in a solution of high specific gravity so that parasitic eggs and cysts float up and get concentrated at the surface. In sedimentation method, the feces is suspended in a solution with low specific gravity so that the eggs and cysts get sedimented at the bottom, either spontaneously or by centrifugation.

### **Floatation Methods**

A simple and popular method is salt floatation using a saturated solution of sodium chloride, having a specific gravity of 1.2. About 2 ml of the salt solution is taken in a flat bottomed tube (or 'penicillin bottle') and 1 g of feces is emulsified in it. The container is then filled completely to the brim with the salt solution and a slide is placed on the container so that it is in contact with the surface of the solution, without any intervening air bubbles after standing for 20-30 minutes, the slide is removed, without jerking, reversed to bring the wet surface on top and examined under the microscope. A coverslip need not be applied if examination is done immediately. Any delay in examination may cause salt crystals to develop, interfering with clarity of vision. This simple method is quite useful for detecting the eggs of the common nematodes such as roundworm (except unfertilised eggs), hookworms and whipworm, but is not applicable for eggs of tapeworms, trematodes and for protozoan cysts.

### **Zinc Sulphate Centrifugal Floatation**

Make a fine suspension of about 1 g of feces in 10 ml of water and strain through gauze to remove coarse particles. Collect the liquid in a small test tube and centrifuge for 1 minute at 2500 RPM. Pour off the supernatant, add water, resuspend and centrifuge in the same manner, repeating the process, till the supernatant is clear. Pour off the clear supernatant, add a small quantity of zinc sulphate solution (specific gravity 1.18 to 1.2) and resuspend the sediment well. Add zinc sulphate solution to a little below the brim and centrifuge at 2500 RPM for 1 minute. Take samples carefully from the surface, using a wire loop, transfer to slide and examine under the microscope. A drop of dilute iodine helps to bring out protozoan cysts better. This technique is useful for protozoan cysts and eggs of nematodes and small tapeworms. But it does not detect unfertilised roundworm eggs, nematode larvae and eggs of most trematodes and of large tapeworms.

### **Sedimentation Methods**

Formol-ether concentration method has been the most widely used sedimentation method. Emulsify 1-2 g. feces in 10 ml water and let large particles sediment. Take supernatant and spin at 2500 RPM for 2-3 minutes. Discard supernatant. Add 10% formol-saline, mix well and stand for 10 minutes. Add 3 ml ether. Shake well. Spin at 2500 RPM for 2-3 minutes. Four layers will form—a top layer of ether, a plug of debris at the interface, the formol-saline layer, and the sediment at the bottom. Carefully detach the debris from

the sides of the tube and discard the top three layers. Suspend the sediment in a few drops of fluid and examine wet mount and iodine preparation. As ether is inflammable and explosive, its use can be hazardous. Ethyl acetate can be conveniently used in its place, with equally good results. The method is useful for all helminth eggs and protozoan cysts.

### **Egg Counts**

A semiquantitative assessment of the worm burden can be made by estimating the number of eggs passed in stools. This is done by egg counts and by relating the counts to the number of worms present by assuming the number of eggs passed per worm per day. However, these are at best approximations and only a rough indication of worm burden can be obtained. Egg counts help to classify helminth infections as heavy, moderate or light. Egg counts can be done by different methods. The standard wet mount gives rough indication of the number of eggs. Ordinarily 1-2 mg of feces is used for preparing a wet film and if all the eggs in the film are counted. The numbers of eggs per gram of feces can be assessed. The modified Kato thick smear technique using 50 mg of stool cleared by glycerine soaked cellophane coverslip can be used for egg counting.

McMaster's egg counting chamber can be used. Here eggs in 20 mg of stool are concentrated by salt floatation on the squared grid on the roof of the chamber, which can be counted. In Stoll's dilution technique, 4g of feces is mixed thoroughly with 56 ml of N/10 NaOH, using beads in a rubber stoppered glass tube. Using a pipette, transfer exactly 0.75 ml of the sample to a slide, apply coverglass and count all the eggs present. The number multiplied by 200 gives the number of eggs per gram of feces. This figure requires to be corrected for the consistency of feces, by multiplying by 1 for hard formed feces, by 2 for mushy formed feces, by 3 for loose stools and by 4 for liquid stools. Watery stools are unfit for counting. Special techniques have been described for particular purposes as for example, Bell's dilution-filtration count for schistosome eggs.

### **Fecal Culture**

Fecal culture is not used for routine diagnosis, but for species identification, as for example in differentiation between *Ancylostoma* and *Necator*. The Harada-Mori culture method uses strips of filter paper on which feces is smeared in the middle third. The paper strips are kept in conical centrifuge tubes with water at the bottom in which the strips dip. The tubes are kept at room temperature in the dark for 7-10 days during which time the larvae develop and fall into the water at the bottom, from which they can be collected.

Charcoal cultures are simple and efficient. Soft or softened feces is mixed with 5-10 parts of moistened charcoal granules and packed into a suitable container and kept covered. In 7-10 days, the larvae hatch and come to the surface. They can be collected by applying on to the surface a pad of soft cotton cloth for half an hour. The cloth is removed and kept upside down on a sedimentation flask filled to the brim with warm water. The larvae fall to the bottom of the flask while the charcoal particles remain on the cloth.

### **EXAMINATION OF BLOOD**

Next to feces, the largest numbers of parasites are found in blood. Blood examination is the routine diagnostic method in malaria, filariasis, African trypanosomiasis and babesiosis. It is sometimes positive in Chagas' disease and rarely in kala-azar and toxoplasmosis. Blood examination is done in the following ways.

#### **Examination for Malarial Parasites**

The standard diagnostic method in malaria is the examination of stained blood films both thin and thick smears.

### ***Thin Smear***

A thin smear is prepared from finger prick, or in infants from heel prick blood. A small drop is spread on a clean grease-free slide with a spreader, to give a uniform smear, ideally a single cell thick. The margins of the smear should be well short of the sides of the slide, and the tail should end a little beyond the centre of its length. The thin smear displays blood cells and parasites clearly. Its only disadvantage is that only a small volume of blood can be surveyed. After drying, the smear is stained with Giemsa or Leishman stain. For Giemsa stain, the smear is fixed in methanol for 3-5 minutes. After drying, Giemsa stain diluted 1 drop in 1 ml of buffered water pH 7-7.2 is applied for 30-45 minutes. The slide is then flushed gently with tap water, dried and examined under the oil immersion objective. The cytoplasm of malarial parasites is stained blue and the chromatin dot red.

For Leishman stain, prior fixation is not necessary as the stain is an alcoholic solution which fixes as it stains. Leishman stain is applied for 30 seconds and diluted with twice its volume of buffered water, pH 7-7.2 and kept for 10 to 15 minutes. The smear is then dried and examined.

For demonstration of malarial parasites, blood should be collected not during the peak of fever, but optimally several hours after it. Bouts of fever follow the synchronous rupture of large number of parasitised erythrocytes releasing their membrane shreds and contents. The emerging merozoites parasites other erythrocytes and initiate a fresh cycle of erythrocytic schizogony. The timing is particularly important in *P.falciparum* infections as here the late stages of schizogony are not seen in peripheral circulation. In practice, the rule is to take a blood smear when a suspected malaria patient is first seen and then again subsequently after a bout of fever. Smears should invariably be collected before starting antimalarial treatment.

In MT malaria, only the ring stage and gametocytes are seen in peripheral smear, while in BT malaria, all stages of schizogony and gametocytes can be seen. Thin smear examination enables the appreciation of changes in the erythrocytes, such as enlargement, alteration of shape, fimbriation, presence of Schuffner's dots or Maurer's clefts. Parasitised erythrocytes are seen most often in the upper and lower margins of the tail of the smear. A minimum of 100 fields should be examined before a negative report is given.

### ***Thick Smear***

Thick smears have the advantage that a larger quantity of blood can be tested. The disadvantages are that the red cells are lysed and the morphology of the parasites is distorted so that identification becomes difficult. A big drop of blood from finger or heel prick is collected on a clean grease-free slide and spread with the corner of another clean slide to form a uniformly thick smear about 1 cm square. The thickness of the smear should be such that the hands of a wristwatch can be seen through it, but not the figures on the dial. The smear is dried in a horizontal position, kept covered from dust. Thick smears have to be dehaemoglobinised before staining. They can be stained with Giemsa or Leishman stains as described above. Wright stain and JSB stain (so called because it was devised by J Singh and Bhattacharjee in 1944) are very useful for staining large numbers of thick films, as in malaria surveys.

Wright's stain consists of two solutions—Solution A contains methylene blue and azure B in phosphate buffer. Solution B contains eosin in phosphate buffer. The film is immersed in solution A for 5 seconds, washed in tap water, immersed in solution B for 5 seconds, washed, dried and examined. Staining times may need adjustment. If the smear is too blue, stain longer in solution B, if too pink, in solution A.

JSB stain also consists of two solutions. The first contains methylene blue, potassium dichromate, sulphuric acid, potassium hydroxide and water. The second solution is aqueous eosin. For staining, the smear is immersed in solution I for 10 seconds, washed for 2 seconds in acidulated water pH 6.2-6.6, stained in solution II for 1 second, washed in acidulated water, immersed again in solution I and washed.



Combined thick and thin smears can be taken on the same slide. Draw a thick line with a glass-marking pencil on a slide, dividing it into two unequal parts. The thick smear is made on the smaller part and the thin smear drawn on the larger. Thick smear is first dehaemoglobinised and the two then stained together. An easy method is to add undiluted Leishman stain over the thin smear and then the diluted stain flooded over to the thick smear also. The stained thin smear is examined first. If the thin smear is negative, the thick smear should be searched for parasites. When a slide is positive for malarial parasites, the report should indicate the species, the developmental stages found and the density of parasites in the smear.

### **Examination for Microfilaria**

Microfilariae may be detected in peripheral blood, both in unstained mounts and in stained smear. In case of nocturnal periodic microfilariae, blood should be collected between 10 PM and 2 AM.

#### **Wet Mount**

Two or three drops of blood are collected on a clean glass slide and a coverslip applied and sealed. The preparation is examined under the low power microscope for the motile microfilariae which can be seen wriggling about, swirling the blood cells in their neighbourhood. The examination may conveniently be deferred till next morning as microfilariae retain their viability and motility for one or two days at room temperature. By using a simple counting chamber, microfilariae in the wet mount can be counted.

#### **Stained Smears**

A thick smear is prepared as for malaria, dehaemoglobinised and stained with Leishman, Giemsa or Delafield's haematoxylin stains. Stained smears have the advantage that the morphology of microfilariae can be studied and species identification made. Thus, for differentiation between *Mf. bancrofti* and *Mf. Malayi* stained smears are necessary. Sometimes microfilariae may be seen in thin smears also.

By using a measured quantity of blood for preparing smears, as for example with a 20 cu mm pipette and counting the total number of microfilariae in the smear, microfilaria counts can be obtained. Multiplying the number of microfilariae in a 20 cu mm smear by 50 gives the count per ml of blood.

#### **Concentration Methods**

These employ venous blood. Two methods are used for concentration of microfilariae sedimentation and filtration.

In *sedimentation method* the sample of blood is first lysed with acetic acid, saponin or other lytic substance, or by freeze thawing and then centrifuged. The sediment is stained and the microfilariae counted. In *filtration method*, a measured quantity (1-5 ml) of blood is collected into an anticoagulant solution and passed through membrane filters fixed on syringes with Swinney filter holder. Blood cells and proteins sticking on to the filter are washed away by repeatedly passing saline through it. The filter is removed, placed on a slide, stained with dilute Giemsa stain and examined under low power microscope for microfilariae. Millipore and Nuclepore membrane filters are available for this purpose, the latter being more sensitive as it can screen larger volumes of blood. The membrane filter method is so much more sensitive than the finger prick method that blood samples taken during day also give reliable results even with nocturnal periodic microfilariae. However, the method has the disadvantages that venepuncture is necessary, membranes are costly and microfilariae may not be in a satisfactory condition for detailed morphological study.

#### **DEC Provocation Test**

Oral administration of diethyl carbamazine (100mg, or 2 mg/kg body weight) brings about mobilisation of microfilariae into peripheral blood. Blood collected 20-50 minutes after the drug is given will show microfilariae so that blood collection can be done during day time. This is a great advantage for surveys. But the drug may cause febrile reactions, particularly in brugianis. It cannot be used in areas endemic for onchocerciasis because of the danger of provoking severe reactions.



## **CULTURE METHODS**

Many parasites can now be grown in culture, but this has not become a routine diagnostic method in parasitic infections. It is sometimes employed for accurate identification of the parasite species. It is more often employed for obtaining large yields of the parasite as a source of antigen, for animal inoculation, drug sensitivity testing, for experimental or physiological studies and for teaching purposes. Some of the culture methods used for different parasites are indicated below.

### **Amoeba**

*E. histolytica* and other intestinal amoebae can be grown in diphasic or monophasic media, in media containing other microorganisms or in axenic cultures. Boeck and Drbohlav's diphasic medium, the classical culture medium for amoeba has been modified by various workers. The medium as used now is basically an egg slant, with an overlay of sterile serum or liver extract in buffered saline. A loopful of sterile rice powder is added to the medium just before inoculation with fresh feces or its saline centrifugal sediment. Cultures can be obtained from feces containing cysts or trophozoites. The cultures are incubated at 37° C and subcultured at 48 hour intervals. Amoebae can be demonstrated in the liquid phase in unstained mounts or stained smears.

Balamuth's monophasic liquid medium is also used commonly for cultivation of amoebae and other intestinal protozoa. This is an egg yolk-liver extract infusion medium. Both protozoa and bacteria present in stools grow in the above media. Bacterial growth can be reduced by addition of penicillin or other antibiotics that do not inhibit protozoa. Axenic cultures (pure cultures without bacteria or other microorganisms) were first developed by Diamond in 1961. Axenic cultivation has enabled precise antigenic and biochemical studies on amoebae. *Balantidium coli* grows well in Balamuth's' medium. *Giardia lamblia* had been established in association with candida and saccharomyces, but axenic cultures were developed in 1970. *Trichomonas vaginalis* grows very well in several commercially available media such as trypticase serum media. Naegleria and Acanthamoeba from CSF can be grown on agar plates heavily seeded with *Escherichia coli*.

### **Leishmania and Trypanosomes**

The classical Nicolle, Novy and Macneal (NNM) medium first described in 1904 for cultivation of leishmania is equally satisfactory for trypanosomes also. This is a defibrinated rabbit blood agar medium. Several modifications of this medium have been introduced.

### **Malaria Parasites**

Cultivation of malaria parasites was first obtained by Bass and Jones in 1912. A simple method of cultivation is as follows. About 10-12 ml of defibrinated or heparinised blood rich in ring forms of malaria parasite, mixed with 0.2 ml of 50% dextrose solution are incubated at 37° C in a sterile test tube in an upright position. The blood separates into the erythrocytes below, plasma above and the buffy coat in between. Malaria parasites grow in the erythrocyte layer immediately below the buffy coat. Smears are collected from this layer at intervals, without tilting the tube.

Segmented schizonts are usually observed after incubation for 24 to 36 hours. The breakthrough in cultivation of malarial parasites came in 1976 when Trager and Jensen successfully maintained *P. falciparum* in continuous cultures in human erythrocytes using RPMI 1640 medium. The cultures are incubated at 38°C with 10% human serum at pH 6.8-7.2 under an atmosphere with 7% CO<sub>2</sub> and 1-5% oxygen. A continuous flow system is used in which the medium flows slowly and continuously over the layer of erythrocytes. The method has been applied to various species of plasmodia. It has been employed for preparation of antigens, for drug sensitivity studies, vaccine tests and many other purposes.

## **ANIMAL INOCULATION**

Animal inoculation is not a routine diagnostic procedure in parasitic infections, but can be used in some instances because of its sensitivity. Animal inoculation can be used for isolating *Toxoplasma gondii* from infected persons. Lymph node or other biopsy materials are inoculated intraperitoneally into immunosuppressed mice. Peritoneal fluid obtained 7-10 days later may show the parasite in Giemsa-stained smears. However, serial passages may be necessary for its isolation. Brain smears may be examined for cysts after sacrificing the mice 3-4 weeks after inoculation. Seroconversion of the animal also indicates a positive result.

Bone marrow, liver, spleen or lymph node aspirates from kala-azar patients injected intraperitoneally into hamsters is a very sensitive method. Even a single amastigote can establish the infection in the animal. Spleen smears taken 4-6 weeks later show LD bodies. Blood from patients with trypanosomiasis can be injected intraperitoneally or into the tail vein of mice or rats. Parasitaemia can be demonstrated in 2 weeks.

## **XENODIAGNOSIS**

This method involves the diagnostic infection of a vector in which the parasite multiplies and can be demonstrated. In *T. cruzi*, diagnosis may be established by letting the vector reduviid bug feed on suspected patients. In 4-5 weeks, live flagellate forms can be seen in the feces of the bugs.

## **IMMUNOLOGICAL DIAGNOSIS**

### **Serology**

Several serological tests have been developed for detection of antibodies to parasites using antigens from cultured parasites or from natural or experimental infections in animals or humans. In some cases antigens are obtained from related parasites or even sometimes from bacteria. Advances in cultivation of parasites have made parasitic antigens more readily available. Cloning of parasitic antigens promises to be a new source. In some instances, diagnosis is attempted by serological demonstration of parasitic antigens in blood, tissues or secretions of suspected patients. Virtually all types of serological reactions have been used. However, serodiagnosis in parasitic infections has only limited value due to various factors. Parasites are complex antigenically and exhibit wide ranging cross-reactions so that serological tests are not sufficiently specific. Another difficulty is in distinguishing between past and current infection. This has been solved partly by looking for IgM antibody, as in amoebiasis and toxoplasmosis.

In general, indirect haemagglutination (IHA), ELISA and counter immune electrophoresis (CIE) are most sensitive; indirect immunofluorescence (IF) and CF moderately sensitive; and simple precipitation in gel and coated particle agglutination least sensitive. Serology has not been very useful in the diagnosis of individual cases, but has been valuable as a screening method in epidemiological surveys. In some infections however where parasites are seldom demonstrable in patients, for example in toxoplasmosis and hydatidosis, serology is of great help. Listed below are some of the applications of serology:

### **Amoebiasis**

Serology is of no value in the diagnosis of acute amoebic dysentery or luminal amoebiasis. But in invasive amoebiasis, particularly in liver abscess, serology is very useful. IHA is most widely employed. Titres of 128 or more are seen in cases of liver abscess.

### **Leishmaniasis**

IHA, IF and CF with leishmania antigen are usually positive in kala-azar. Tests using the acid-fast Kedrowsky bacillus are relatively less sensitive.

### **Malaria**

IF, ELISA and IHA are sensitive and specific, but are not useful for diagnosis of acute malaria because antibodies persist for some years after cure. A negative test may however help to exclude malaria.

Serological tests are useful in epidemiological surveys for malaria. Molecular assays such as antigen capture have been applied for developing rapid dip-stick tests (e.g. ParaSight-F in MT malaria).

### ***Toxoplasmosis***

Serological tests offer the most useful diagnostic method in toxoplasmosis. The original Sabin-Feldman dye test, though very specific and sensitive, is no longer in use. IF, IHA and CF were other useful tests. The dye test remains positive for life, while CF tests become negative soon after active infection. At present ELISA is routinely used in toxoplasma serology. It is very informative as it provides titres of IgM and IgG antibody separately for better interpretation of the results.

### ***Intestinal Helminths***

Antibodies can be demonstrated in most intestinal helminthiases, but extensive crossreactions limit their use in diagnosis.

### ***Trichinosis***

Serology is very useful in diagnosis of trichinosis. Bentonite flocculation slide tests and CF become positive 3-4 weeks after infection. IF becomes positive even earlier. ELISA is also available. Demonstration of seroconversion is diagnostic.

### ***Toxocariasis***

High titres in serological tests are obtained in visceral larva migrans, but specificity is low due to cross-reactions with intestinal nematode antigens.

### ***Filariasis***

IHA and bentonite flocculation tests with antigen from *Dirofilaria immitis* gives positive reaction in patients, and high titres in tropical pulmonary eosinophilia. But crossreactions are frequent.

### ***Echinococcosis***

Several serological tests have been developed using hydatid fluid or scolex antigens from hydatid cysts in sheep. IHA, IF and ELISA are very sensitive. Cross-reactions occur with cysticercosis.

### ***Skin Tests***

Intradermal tests have been used in many parasitic infections. They are sensitive and persist for many years, sometimes even for life. But specificity is relatively low. Casoni's test had been used widely in the diagnosis of hydatid disease since its original description in 1911. The antigen is sterile hydatid fluid drawn from hydatid cysts from cattle, sheep, pig or humans, filtered and tested for sterility. Intradermal injection of 0.2 ml of the antigen induces a wheal and flare reaction within 20 minutes in positive cases. A saline control is used. False-positive tests are seen in schistosomiasis and some other conditions. Casoni's test is now largely replaced by serological tests. Leishmanin test is sensitive and relatively specific. The antigen is obtained from cultured leishmania and consists of killed promastigotes in phenol saline. Intradermal injection of 0.1 ml induces a papule 5 mm or more in diameter in 48-72 hours. This delayed hypersensitivity test is positive in cutaneous leishmaniasis and negative in diffuse cutaneous and visceral leishmaniases.

### ***Antiprotozoal Therapy***

Antiprotozoal drugs are a class of medication used to treat infections caused by protozoa, which are single cell organisms that belong to the type of parasites. Protozoal infections occur throughout the world and are a major cause of morbidity and mortality in some regions such as Africa and South-East Asia. Common types of protozoal infections and associated symptoms are:

1. Malaria – it is transmitted by the bite of infected mosquitoes in tropical and subtropical areas of the world. Symptoms include fever, chills, sweating, headache, muscle aches, vomiting and diarrhoea. The very serious consequences of the disease are mental disturbances, convulsions and various blood and kidney disorders. These can lead to death sometimes within 24 hours since infection.

2. Giardiasis – it is an intestinal infection, which usually found in areas with poor sanitation and unsafe water. Infection occurs by swallowing contaminated water, by eating contaminated food or through contact with infected person. Diarrhoea is the most common symptom of giardiasis. Other symptoms include abdominal cramps, bloating, nausea and flatulence.

3. Trichomoniasis – it is a protozoal infection acquired through sexual contact. Females may present with vaginal itchiness and odorous yellow vaginal discharge. Males usually do not have any symptoms, although occasionally they may have painful urination and purulent urethral discharge.

#### Classes of oral antiprotozoal drugs

Commonly used oral antiprotozoal drugs can be generally classified into two main groups: antimalarial drugs and miscellaneous antiprotozoals. In addition to their use as antiprotozoals, some of them such as metronidazole and doxycycline are also used for treating bacterial infections.

The actions of antiprotozoal drugs against the infections are complex and are not fully understood. Some of them may interfere with reproduction of or damage protozoal DNA to limit the spread of an infection. Most of the oral antiprotozoal drugs are prescription-only medicines and are available in various dosage forms such as tablets and capsules. They should only be used under close supervision by healthcare professionals.

#### Antimalarial drugs

Antimalarial drugs include mefloquine, chloroquine, proguanil with atovaquone and doxycycline. They kill or inhibit the growth of protozoa by affecting different stage of the parasitic life cycle. They are used both to treat and prevent malaria. For prevention of malaria, the choice of drugs is based on the destinations you are going to visit, the risks as determined by your travelling behaviour and your previous health status. For treatment of malaria, the type of antimalarial drug and the length of treatment will depend on the type of malaria you have, the severity of your symptoms, where you caught malaria and whether you have taken an antimalarial to prevent malaria. If you have taken an antimalarial as a preventative measure, the same type of antimalarial should not be used to treat malaria. It is therefore important to tell your doctor which antimalarial you have previously taken. Besides, your doctor may recommend using a combination of different antimalarial drugs to overcome strains of malaria that have become resistant to single types of medication.

#### Miscellaneous antiprotozoals

Commonly used miscellaneous antiprotozoals include metronidazole, tinidazole and nifuratel.

Metronidazole is the most common treatment for trichomoniasis and giardiasis. Its action in the treatment of protozoal infections remains poorly understood, however, it may work by damaging protozoal DNA.

Tinidazole works as well as metronidazole and has many of the same side effects, but it can be given in a single dose. Whereas, nifuratel can be used as an alternative to metronidazole or tinidazole in the treatment of trichomoniasis.

#### Common side effects and precautions of oral antiprotozoal drugs

Antiprotozoal drugs	Common side effects	Precautions
<b>Antimalarial drugs</b>		
Mefloquine	<ul style="list-style-type: none"> <li>Nausea and vomiting</li> </ul>	Use with caution in patients with

	<ul style="list-style-type: none"> <li>• Dyspepsia</li> <li>• Abdominal pain</li> <li>• Diarrhoea</li> <li>• Dizziness</li> <li>• Headache</li> <li>• Insomnia and vivid dreams</li> </ul>	<p>epilepsy, seizures, depression or other</p> <p>mental health problems, severe heart or</p> <p>liver problems</p>	
Chloroquine	<ul style="list-style-type: none"> <li>• Gastrointestinal disturbances</li> <li>• Headache</li> <li>• Hypotension</li> <li>• Convulsions</li> <li>• Visual disturbances</li> <li>• Depigmentation or loss of hair</li> <li>• Rashes and pruritus</li> </ul>	<p>Use with caution in patients with</p> <p>neurological disorders, myasthenia gravis</p> <p>(a condition with muscle fatigue and weakness), glucose-6-phosphate dehydrogenase</p> <p>(G6PD, an enzyme which helps red blood cells function normally) deficiency, liver and renal problems</p>	
Proguanil with atovaquone	<ul style="list-style-type: none"> <li>• Nausea and vomiting</li> <li>• Abdominal pain</li> <li>• Diarrhoea</li> <li>• Cough</li> <li>• Headache</li> <li>• Dizziness</li> <li>• Insomnia and abnormal dreams</li> <li>• Depression</li> <li>• Anorexia</li> <li>• Fever</li> <li>• Skin Rash</li> </ul>	<p>Should not be given to pregnant or breast feeding women</p> <p>Not recommended for patients with severe kidney problems.</p>	
Doxycycline	<ul style="list-style-type: none"> <li>• Nausea and vomiting</li> <li>• Diarrhoea</li> <li>• Difficulty in swallowing</li> <li>• Oesophageal irritation</li> <li>• Cause yellow teeth and teeth</li> </ul>	<p>Should not be given to pregnant or breastfeeding women or children under 12 years</p> <p>Not recommended for patients with kidney, liver disease</p> <p>Tablets or capsules should be swallowed whole</p>	



	disfigurement if taken during teeth development	<p>with plenty of fluid and taken with food.</p> <p>Patients should not lie down for about half an hour</p> <p>Afterwards Avoid taking with antacids, milk, calcium magnesium salts</p> <p>Photosensitivity may occur rarely. Avoid prolonged sun exposure and use appropriate sunscreen</p>	
<b>Miscellaneous antiprotozoals</b>			
Metronidazole and Tinidazole	<ul style="list-style-type: none"> <li>• Nausea and vomiting</li> <li>• Unpleasant metallic taste</li> <li>• Furred tongue</li> <li>• Oral mucositis</li> <li>• Anorexia</li> </ul>	<p>Avoid drinking alcohol beverages</p> <p>Use with caution in patients with blood disorders, central nervous system disease and severe hepatic impairment</p> <p>Should not be given to pregnant women</p>	
Nifuratel	<ul style="list-style-type: none"> <li>• Gastrointestinal disturbances</li> <li>• Damage to the peripheral nervous system</li> <li>• Easy or excessive bruising and bleeding</li> </ul>	<p>Should not be given to patients with renal impairment, neuropathies or G6PD deficiency</p>	

**Possible Questions**

**Part B (Two marks)**

1. What is trophozoite?
2. Write a detailed note on Protozoa?
3. Explain the classification of Protozoa.
4. What is cyst?
5. Define phagocytosis.
6. Define pinocytosis.
7. List out the four phyla of medically important protozoan parasite.
8. Define pseudopodia.
9. What are the different types of amoebae which are medically important?
10. What are the different types of motility present in protozoa?
11. Define Apical complex.

**Part B (Eight marks)**

1. What is Amoebae? Give four examples for parasitic amoebae.
2. Explain the classification of Protozoa.
3. List out the general properties of Protozoans.
4. Discuss about the laboratory techniques in Parasitology.
5. Explain in detail about two types of blood smear preparation.
6. How will you collect the samples for protozoal infection?
7. How will you perform the cyst analysis?
8. Write a detailed note on antiprotozoan therapy?
9. Discuss in detail about concentration method.

	<b>Unit III</b>	Option 1	Option 2	Option 3	Option 4	Answer
1	which of the following is non – pathogenic	Entamoeba coli	Entamoeba histolytica	Balantidium coli	Trichomonas vaginalis	Entamoeba coli
2	Amphotericin B is effective treatment for all the following except	Leishmaniasis	Amoebiasis	Naegleria infection	Acanthamoeba infection	Amoebiasis
3	Which of the following is not an antiprotozoal drug:	Albendazole	Tetracycline	Trimethoprin+sulfamethoxazole	Pyrimethamine	Albendazole
4	Which of the following is not a flagellate :	Naegleria	Giardia	Leishmania	Dientamoeba	Naegleria
5	Montenegro skin test used to be done for the diagnosis of	Kala-azar	Hydatid disease	Toxocariasis	Cysticercosis	Kala-azar
6	Amoebiasis can mimic in clinical presentation with :	Appendicitis	Schistosomiasis	Toxocariasis	Cysticercosis	Appendicitis
7	Entamoeba histolytica gains access to the liver via	Lymphatics	Portal system	Direct invasion	Through perineural space	Portal system
8	In case of hepatic amoebiasis ESR is	Normal	Almost always elevated	Below normal	Variable	Almost always elevated
9	Meningoencephalitis due to Naegleria fowleri best respond to	Amphotericin B	Chloroquine	Metronidazole	Tetracycline	Amphotericin B
10	Malabsorption seen in giardiasis is most likely due to	Mechanical barrier to absorption	Poor enzymatic digestion	Insolubilising the proteins and fats	Direct invasion	Mechanical barrier to absorption
11	Which of the following use pseudopodia for locomotion	Ciliates	Amoebae	Flagellates	Microsporidia	Amoebae
12	A host that harbours the larval or asexual stage of parasite is known as	Definite host	Intermediate host	Reservoir host	None of the above	Intermediate host
13	Ribbon like helminth parasites are known as	Tapeworms	Flukes	Round worms	Amoeba	Tapeworms
14	The test for an accurate	Direct wet	Permanent	PCR	Serological test	Permanent

	faecal examination for ova and cysts is	mount for motility	stained side			stained side
15	The best test to distinguish amoebic liver abscess from a bacterial liver abscess is	Ultra sound examination	Good physical examination by an expert	CT scan	Serological evidence of E. histolytica	Serological evidence of E. histolytica
16	There is 100 percent infection in Giardia lamblia when the number of ingested cysts is	100 or more	1,000 or more	1,000 or more	100,000 or more	100 or more
17	A 'pear shaped' trophozoite is normally seen in	Entamoeba histolytica	Giardia lamblia	B.coli	Dientamoeba fragilis	Giardia lamblia
18	A 30-years –old male who is anaemic, cachexic and has hepatosplenomegaly accompanied with fever, shows on a bone marrow smear many organisms within macrophages. These organisms have a nucleus and a smaller but distinct kinetoplast. The likely diagnosis is	Leishmania donovani	Histoplasma capsulatum	Toxoplasma gondi	Toxocara canis	Leishmania donovani
19	Blood smears for suspected malaria should first be taken	Just after the fever	Before the chills	When the diagnosis is first suspected	At night	When the diagnosis is first suspected
20	After initiation of specific treatment in malaria, how soon the patient, s symptoms abate	Within 6 hour	Within 24-48 hours	within a week	After one more febrile attack	Within 24-48 hours
21	Which of the following is not a component of Lugol's iodine	Potassium iodide	Iodine crystals	Ethyl alcohol	Water	Ethyl alcohol
22	All the following are	Good overall	Easy to prepare	Long shelf- life	Preserves	Preserves

	advantages of using formalin in preservation of stool except	fixative			trophozoites	trophozoites
23	A series of 3 stool specimens for diagnosis of parasitic infections be examined within no more than	2 days	4 days	7days	10 days	10days
24	The aldehyde test is based on the principle of	Altered WBC: RBC ratio	Altered albumin: globulim ratio	Decreased cell mediated immunity	. Antigen antibody complement complex formation	Altered albumin: globulim ratio
25	“Eating at the same table” would be an appropriate description of	Parasitism	Symbiosis	Commenalism	Mutualism	Commenalism
26	A chest X-ray in cases of pneumonia due to pneumocystis carinii can reveal all the following except	Cavitation	Nodular densities	Ground glass appearance	Lobar infiltration	Cavitation
27	Treatment of choice for vaginitis due to trichomonas vaginalis is	Metronidazole	Thiabendazole	Piperazine	Chloroquine	Metronidazole
28	The partner of a Patient who suffers from trichomonal vaginitis be treated	Only if symptomatic	Only if examination is positive	Always be treated	No need of treatment	Always be treated
29	What percentage of males infected with Trichomonas vaginalis are symptomatic?	Nil	5-10%	10-15%	50-60%	10-15%
30	Chagas’ disease is usually treated with	Nifurtimox	Niclosamide	Spraziquantel	Ivermectin	Nifurtimox
31	Stains used for parasite	Grams stain	Iron hematoxylin	Nigrosine stain	Giemsa Stain	Iron hematoxylin



	observation include ...		stain			stain
32	Using blood films which of the following infections can be identified?	Trichomonas	Entameoba	Plasmodium	Ascaris	Plasmodium
33	..... Film allows rapid confirmation of presence of parasite in the blood.	Thick	Thin	Hot	Cold	Thick
34	..... film is used to identify the species of parasite.	Thick	Thin	Hot	Cold	Thin
35	Cerebrospinal fluid is collected by ..... puncture	Spinal	Bone marrow	Liver	Spleen	Spinal
36	The adult worm of <i>Chlonorchisa sinensis</i> is most frequently found in	Intrahepatic bile duct	Lung parenchyma	Urinary bladder submucosa	Lumen of Intestine	Intrahepatic bile duct
37	The drug of choice for treating cryptosporidiosis is	Pyrimethamine	Metronidazole	Tetracycline	There is no effective treatment	There is no effective treatment
38	The drug of choice for balantidiasis is	Metronidazole	Oxytetracycline	Chloroquine	Albendazole	Oxytetracycline
39	Which of the following drug used to treat infection with Loa loa and kills worms by causing flaccid paralysis	Invermectin	Metronidazole	suramin	mefloquine	Invermectin
40	Nucleus of Entamoeba coli has	Central karyosome	Peripheral or eccentric karyosome	No karyosome	Many karyosomes	Peripheral or eccentric karyosome
41	Parasites causing human infections can be divided into ..... groups.	Two	Three	Four	Five	Two
42	Protozoan parasites consists of ..... Cell	Multiple	Single	Row	Double	Single
43	Protozoan parasites that	Apicomplexa	Microspora	Kinetoplastida	Retortamonadida	Apicomplexa

	infect humans include ...					
44	A parasite that lines inside the body of a host is ...	Endoparasite	Ectoparasite	Obligate parasite	Facultative parasit	Endoparasite
45	..... Technique is used to separate parasitic ova and cysts from most of the fecal matter	Floatation	Sublimation	Filtration	Concentration	Floatation
46	Which of the following causes amoebic meningo encephalitis ?	Entamoeba histolytica	Entamoeba Coli	Entamoeba gingivalis	Naeglaria fowleri	Naeglaria fowleri
47	Which of the following causative agent is not transmitted by mosquito:	Plasmodium vivax	Brugia malayi	Wuchereria bancrofti	Loa loa	Loa loa
48	Ticks are the vectors in which of the following	Malaria	Babesiosis	Loiasis	Chagas' disease	Babesiosis
49	All the following parasites can be present in spleen except	Leishmania donovani	Plasmodium falciparum	Plasmodium vivax	Balantidium coli	Balantidium coli
50	Which of the following requires two intermediate host for completion of its life cycle	Taeniasolium	Diphyllobothrium latum	Hymenolepis nana	Taenia saginata	Diphyllobothrium latum
51	The invasion of tissue by parasites elicits production of antibodies that include	IgM	Protein	Aminoacid	Peptidoglycan	IgM
52	Carbolic acid is the name commonly referred for	Phenol	Methyl alcohol	Ethyl alcohol	Potassium dichromate	Phenol
53	Parasite F test is used for the diagnosis of	Filariasis	Falciparum malaria	Amoebiasis	Cysticercosis	bFalciparum malaria
54	Entero-test capsule is used for sampling	Duodenal conte	CSF	Urogenital specimens	Rectal smear	Duodenal conte
55	Modified acid fast staining is used for demonstration of:	Leishmania donovani	Isospora belli	Pneumoystis carini	Entamoeba fragilis	Pneumoystis carini

56	The length of adult worm of <i>Diphyllobothrium latum</i> could be up to	2 metres	5 metres	10 metres	20 metres	10 metres
57	Chronic infection with which of the following may be associated with megaesophagus or megacolon	<i>Trypanosoma cruzi</i>	<i>Trypanosoma gambiense</i>	<i>Leishmania tropica</i>	<i>Leishmania donovani</i>	<i>Trypanosoma cruzi</i>
58	Adult worms of which of the following are found in subcutaneous nodules	<i>Loa loa</i>	<i>Dracunculus medinensis</i>	<i>Onchocerca volvulus</i>	<i>Brugia malayi</i>	<i>Onchocerca volvulus</i>
59	Amastigotes of <i>leishmania</i> are found in	Liver parenchymal cell	In- vitro culture	Salivary gland of sandfly	Human mononuclear phagocytes	Human mononuclear phagocytes
60	Cysts of all the following intestinal protozoa have 4 or more nuclei except	<i>Entamoeba histolytica</i>	<i>Entamoeba coli</i>	<i>Iodamoeba butschlii</i>	<i>Entamoeba hartm</i>	<i>Iodamoeba butschlii</i>

**UNIT-IV**  
**SYLLABUS**

Protozoan infections - *Entamoeba histolytica*, *Plasmodium falciparum*, *Leishmania donovani* - *Giardia intestinalis* *Trichomonas vaginalis*, *Toxoplasma gondii*, *Pneumocystis carinii*, *Balantidium coli*.

**PROTOZOAN INFECTIONS**

***ENTAMOEBA HISTOLYTICA***

**History**

*Entamoeba histolytica* was discovered in 1875 by Losch in the dysenteric feces of a patient in St Petersburg, Russia. He also observed it in colonic ulcers at autopsy and produced dysentery in a dog by inoculation through the rectum. In 1890, William Osler reported the case of a young man with dysentery who later died of liver abscess. Councilman and Lafleur in 1891 established the pathogenesis of intestinal and hepatic amoebiasis and introduced the terms 'amoebic dysentery' and 'amoebic liver abscess.'

**Geographical Distribution**

*E. histolytica* is world-wide in prevalence. It is much more common in the tropics than elsewhere, but it has been found wherever sanitation is poor, in all climatic zones, from Alaska (61° N) to the Straits of Magellan (52°S). It has been reported that about 10 per cent of the world's population and 50 per cent of the inhabitants

of some developing countries may be infected with the parasite. The infection is not uncommon even in affluent countries, about 1 per cent of Americans being reported to be infected. While the large majority of the infected are asymptomatic, invasive amoebiasis causes disabling illness in an estimated 50 million persons and death in 50,000 annually, mostly in the tropical belt of Asia, Africa and Latin America.

It is the third leading parasitic cause of mortality, after malaria and schistosomiasis. *E. histolytica* is found in the human colon. Natural infection also occurs in monkeys, dogs and probably in pigs also but these animals do not appear to be relevant as sources of human infection. Infection is mostly asymptomatic. It commonly occurs in the lumen of the colon as a commensal, but sometimes invades the intestinal tissues to become a pathogen.

**Morphology**

*E. histolytica* occurs in three forms—the trophozoite, precystic and cystic stages.

***Trophozoite***

The trophozoite or the vegetative form is the growing or feeding stage of the parasite. It is irregular in shape and varies in size from about 12 to 60 µm. It is large and actively motile in freshly passed dysenteric stools, while in convalescents and carriers, it is much smaller. The parasite as it occurs free in the lumen as a commensal is generally smaller in size, about 15 to 20 µm and has been called the *minuta* form.

The protoplasm is differentiated into a thin outer layer of clear, transparent, refractive ectoplasm and an inner finely granular endoplasm having a ground glass appearance. Pseudopodia are formed by a sudden thrusting movement of the ectoplasm in one direction, followed by the streaming in of the whole endoplasm. The direction of movement may be changed suddenly, with another pseudopodium being formed at a different site, when the whole cytoplasm flows in the direction of the new pseudopodium. Typical amoeboid motility is a crawling or gliding movement and not a free-swimming one. The cell has to be attached to some surface or particle for it to move. In culture tubes, the trophozoites may be seen crawling up the side of the glass tube. Pseudopodium formation and motility are inhibited at low temperatures.

The endoplasm contains the nucleus, food vacuoles and granules. The nucleus is not clearly seen in the living trophozoite, but can be distinctly demonstrated in preparations stained with iron-haematoxylin or Gomori's trichrome stains. The nucleus is spherical, 4 to 6 µm in size and contains a small central

karyosome surrounded by a clear halo. The karyosome is anchored to the inner surface of the nuclear membrane by fine radiating fibrils called the linin network giving a 'cartwheel appearance.'

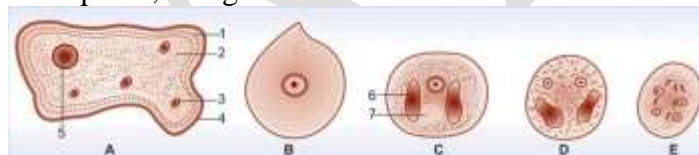
The delicate nuclear membrane is lined by a rim of chromatin distributed evenly as small granules. The trophozoites from acute dysenteric stools often contain phagocytosed erythrocytes. This feature is diagnostic as phagocytosed red cells are not found in any other commensal intestinal amoebae. The trophozoite divides by binary fission once in about 8 hours. Trophozoites are delicate organisms and are killed by drying, heat and chemical disinfectants. They do not survive for any length of time in stools outside the body. Therefore, the infection is not transmitted by trophozoites. Even if live trophozoites from freshly passed stools are ingested, they are rapidly destroyed in the stomach and cannot initiate infection.

### ***Precystic Stage***

Some trophozoites undergo encystment in the intestinal lumen. Encystment does not occur in the tissues nor in feces outside the body. Before encystment the trophozoite extrudes its food vacuoles and becomes round or ovoid about 10 to 20  $\mu\text{m}$  in size. This is the precystic stage of the parasite. It secretes a highly refractile cyst wall around it and becomes the cyst.

### ***Cystic Stage***

The cyst is spherical, about 10 to 20  $\mu\text{m}$  in size. The early cyst contains a single nucleus and two other structures—a mass of *glycogen* and one to four *chromatoid bodies* or *chromidial bars*, which are cigar-shaped or oblong refractile rods with rounded ends. The chromatoid bodies are so called because they stain with haematoxylin like chromatin. As the cyst matures, the glycogen mass and chromidial bars disappear. The nucleus undergoes two successive mitotic divisions to form two and then four nuclei. The mature cyst is quadrinucleate. The nuclei and chromidial bodies can be made out in unstained films, but they appear more prominently in stained preparations. With iron-haematoxylin stain the nuclear chromatin and the chromatoid bodies appear deep blue-black, while the glycogen mass appears unstained. When stained with iodine the glycogen mass appears golden brown, the nuclear chromatin and karyosome bright yellow and the chromidial bars appear as clear spaces, being unstained.



**FIGURE:** *Entamoeba histolytica*. (A) Trophozoite; (B) Precystic stage; (C) Uninucleate cyst; (D) Binucleate cyst; (E) Mature quadrinucleate cyst; 1—Ectoplasm; 2—Endoplasm; 3—Ingested erythrocytes; 4—Pseudopodium; 5—Nucleus; 6—Chromidial bar; 7—Glycogen mass

### ***Life Cycle***

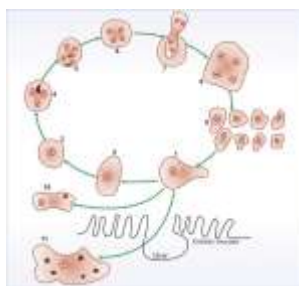
The infective form of the parasite is the mature cyst passed in the feces of convalescents and carriers. The cysts can remain viable under moist conditions for about ten days. The cysts ingested in contaminated food or water pass through the stomach undamaged and enter the small intestine.

When the surrounding medium becomes alkaline. The cyst wall is damaged by trypsin in the intestine, leading to excystation. The cytoplasm gets detached from the cyst wall and amoeboid movements appear causing a tear in the cyst wall through which the quadrinucleate amoeba emerges. This stage is called the *metacyst*. The nuclei in the metacyst immediately undergo division to form eight nuclei, each of which gets surrounded by its own cytoplasm to become eight small amoebulae or metacystic trophozoites. If excystation takes place in the small intestine, the metacystic trophozoites do not colonise there, but are carried to the caecum.



The optimum habitat for the metacystic trophozoites is the caecal mucosa where they lodge in the glandular crypts and undergo binary fission. Some develop into precystic forms and cysts, which are passed in feces to repeat the cycle.

The entire life cycle is thus completed in one host. Infection with *E. histolytica* does not necessarily lead to disease. Infact, in most cases it remains within the lumen of the large intestine, feeding on the colonic contents and mucus as a commensal without causing any ill effects. Such persons become carriers or asymptomatic cyst passers, as their stool contains cysts. They are responsible for the maintenance and spread of infection in the community. The infection may get spontaneously eliminated in many of them. Sometimes, the infection may be activated and clinical disease ensues. Such latency and reactivation are characteristic of amoebiasis.



**FIGURE:** Life cycle of *E. histolytica*. (1) Trophozoite in gut lumen, (2) Precystic form, (3) Uninucleate cyst, (4) Binucleate cyst, (5) Quadrinucleate cyst, passed in faeces, (6) Mature cyst—infective when ingested, (7) Excystation in small intestine, (8) Metacystic form, (9) Eight daughter amoebulae, (10) Trophozoite shed in faeces—cannot encyst, (11) Tissue form of trophozoite in colonic ulcer—shows ingested erythrocytes



**FIGURE:** Life cycle of *E. histolytica* (Schematic)

### Culture

Boeck and Drbohlav reported the successful cultivation of *E. histolytica* in 1925 using an egg slant-Locke's solution diphasic medium. A monophasic liquid medium was described by Balamuth in 1946. Robinson's medium has been widely used for cultivation of amoebae. In these media and their modifications, amoebae grow only in presence of enteric bacteria or other protozoa and starch or other particles. Axenic cultivation which does not require the presence of other microorganisms or particles, was first developed by Diamond in 1961. This yields pure growth of the amoeba and has been very useful for physiological, immunological and pathogenicity studies of amoebae.

### Pathogenicity

The lumen dwelling amoebae do not cause any illness. Only when they invade the intestinal tissues do they cause disease. This happens only in about 10 per cent of cases of infection, the remaining 90 per cent being asymptomatic. The factors that determine tissue invasion are not fully understood. Not all strains of *E. histolytica* are pathogenic or invasive. All strains can adhere to host cells and induce proteolysis of host cell contents *in vitro* but only pathogenic strains can do so *in vivo*. Differentiation between pathogenic (P) and non-pathogenic (NP) strains can be made by several methods including susceptibility to complement mediated lysis and phagocytic activity or by the use of genetic markers or monoclonal antibodies. Amoebic

cysteine proteinase which inactivates the complement factor C3 is an important virulence factor of P strains. Based on electrophoretic mobility of 6 isoenzymes (acetylglucosaminidase, aldolase, hexokinase, NAD-diaphorase, peptidase, phosphoglucomutase), *E.histolytica* strains can be classified into at least 22 zymodemes. Of these only 9 are invasive (P) and the rest are noninvasive (NP) commensals. The zymodemes show a geographical distribution. Even in endemic areas, NP zymodemes are far more common than P ones, which account only about 10 per cent of the total population.

It has been proposed that P and NP strains though morphologically identical may represent two distinct species—the P strains being *E.histolytica*, and the NP strains reclassified as *E.dispar*. Trophozoites of *E.dispar* contain bacteria, but no RBC. Host factors such as stress, malnutrition, alcoholism, corticosteroid therapy and immunodeficiency may influence the outcome of infection. Some glycoproteins in colonic mucus bind avidly to surface receptors of the amoeba trophozoites, blocking their attachment to epithelial cells. Alteration in the nature and quantity of colonic mucus may, therefore, influence virulence. Virulence may also be conditioned by the bacterial flora in the colon.

The metacystic trophozoites penetrate the columnar epithelial cells in the crypts of Lieberkuhn in the colon. Penetration is facilitated by the tissue lytic substances released by the amoebae which damage the mucosal epithelium and by the motility of the trophozoite. Mucosal penetration by the amoeba produces discrete ulcers with pinhead centre and raised edges. Sometimes the invasion remains superficial and confined to the mucosal epithelium leading to erosion which may spread laterally.

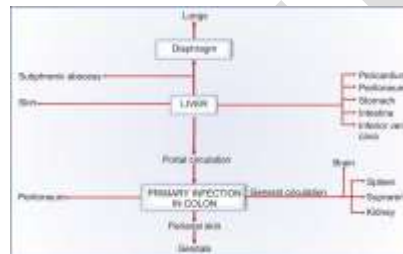
These heal spontaneously without any ill effects. More often, the amoebae make their way to the submucosal layer where they multiply rapidly and form colonies, destroying the tissues around by lytic necrosis and forming an abscess. The abscess breaks down to form an ulcer. Amoebic ulcer is the typical lesion seen in intestinal amoebiasis. The ulcers are multiple and confined to the colon, being most numerous in the caecum and next in the sigmoido-rectal region. The intervening mucous membrane between the ulcers remains healthy. Ulcers appear initially on the mucosa as raised nodules with pouting edges. They later break down discharging brownish necrotic material containing large numbers of trophozoites. The typical amoebic ulcer is flask-shaped in cross section, with mouth and neck being narrow and the base large and rounded. Multiple ulcers may coalesce to form large necrotic lesions with ragged or undermined edges and covered with brownish slough. The ulcers generally do not extend deeper than the submucous layer, but amoebae spread laterally in the submucosa causing extensive undermining and patchy mucosal loss. Amoebae are seen at the periphery of the lesions and extending into the surrounding healthy tissues. Occasionally, the ulcers may involve the muscular and serous coats of the colon, causing perforation and peritonitis. Blood vessel erosion may cause haemorrhage.

The superficial lesions generally heal without scarring, but the deep ulcers form scars which may lead to strictures, partial obstruction and thickening of the gut wall. Occasionally, a granulomatous growth may develop on the intestinal wall from a chronic ulcer. This amoebic granuloma or *amoeboma* may be mistaken for a malignant tumour. During its invasion of the intestinal wall, amoebae often penetrate radicles of the portal vein and are transported through the portal circulation to the liver. Most of them fail to lodge, but some manage to get established in the hepatic lobules, where they multiply and initiate lytic necrosis with little inflammatory reaction.

Hepatic invasion is multifocal, the right lobe being more affected. With increasing size of the lesions and continuing necrosis, there occurs considerable leucocytic infiltration. There is also an enlargement of the liver. This stage is known as *amoebic hepatitis*. One or more of the lesions in the liver may extend peripherally to develop into *amoebic abscesses*. Which may vary in size from a few millimeters to several centimeters. The centre of the abscess contains thick chocolate brown pus ('anchovy sauce pus') which is liquefied necrotic liver tissue. It is bacteriologically sterile and free of amoebae. Immediately surrounding

the central necrotic area is a median zone consisting only of coarse stroma. At the periphery is almost normal liver tissue, which contains invading amoebae. If the abscess has developed rapidly, there may be no limiting capsule other than liver tissue, but more chronic lesions are surrounded by a fibrous wall. Liver abscess may be multiple or more often solitary, usually located in the upper right lobe of the liver. Jaundice develops only when lesions are multiple or when they press on the biliary tract. Untreated abscesses tend to rupture into the adjacent tissues and organs, through the diaphragm into the lung or pleural cavity, into the pericardium, peritoneal cavity, stomach, intestine or inferior vena cava, or externally through the abdominal wall and skin.

Very rarely, amoebiasis of the lung may occur by direct haematogenous spread from the colon, without hepatic involvement, but it is most often due to direct extension from the liver by an abscess rupturing through the diaphragm. It is, therefore, most common in the lower part of the right lung. A hepatobronchial fistula usually results, with expectoration of chocolate brown sputum. Less often, an amoebic empyema develops.



**FIGURE:** Sites affected in amoebiasis

Involvement of distant organs is by haematogenous spread. Instances are abscesses in the brain, spleen, adrenals and kidneys. Cutaneous amoebiasis is by direct spread, from the rectum perianally and from colostomy openings and sinuses draining liver abscesses. Extensive necrosis and sloughing occur. Trophozoites can be demonstrated in the lesions. It can also occur as a venereal infection of the penis following anal intercourse.

### **Clinical Features**

The incubation period is highly variable, from 4 days to a year or longer. On an average it is from 1 to 4 months. The clinical course is characterised by prolonged latency, relapses and intermissions. Amoebiasis can present in different forms and degrees of severity depending on the organ affected and the extent of damage caused. It can be classified as intestinal and extraintestinal amoebiasis.

### **Intestinal Amoebiasis**

The clinical picture covers a wide spectrum from noninvasive carrier state to fulminant colitis. The typical manifestation of intestinal amoebiasis is amoebic dysentery. This may resemble bacillary dysentery, but can be differentiated on clinical and laboratory grounds. Compared to bacillary dysentery, it is usually insidious in onset and the abdominal tenderness less and localised.

The stools are large, foul smelling and brownish black, often with blood streaked mucus intermingled with faeces. The red blood cells in stools are clumped and reddish brown in colour. Cellular exudate is scanty. Charcot-Leyden crystals are often present. *E.histolytica* trophozoites can be seen containing ingested erythrocytes. The patient is usually afebrile and nontoxic. In fulminant colitis there is confluent ulceration and necrosis of colon. The patient is febrile and toxic.

Intestinal amoebiasis does not always result in dysentery. Quite often there may be only diarrhoea or vague abdominal symptoms popularly called 'uncomfortable belly' or 'growling abdomen.' Chronic involvement of the caecum causes a condition simulating appendicitis.

### ***Extraintestinal Amoebiasis***

Hepatic involvement is the most common extraintestinal complication of amoebiasis. Though trophozoites reach the liver in most cases of amoebic dysenteries, only in a small proportion do they manage to lodge and multiply there. Several patients with amoebic colitis develop an enlarged tender liver without detectable impairment of liver function or fever. This acute hepatic involvement (amoebic hepatitis) may be due to repeated invasion by amoebae from an active colonic infection or to toxic substances from the colon reaching the liver. It is probable that liver damage may be caused not directly by the amoebae, but by lysosomal enzymes and cytokines from the inflammatory cells surrounding the trophozoites. In about 5 to 10 per cent of persons with intestinal amoebiasis, liver abscess may ensue. It is more common in adult males. The patient feels heaviness and pain in the liver area and referred pain around the right shoulder. Fever with chills is common, as also weight loss. Jaundice is not common.

Pleuropulmonary amoebiasis usually follows extension of hepatic abscess through the diaphragm and therefore, the lower part of the right lung is the usual area affected. Very rarely, abscess formation may occur at any site on either lung due to haematogenous spread. The abscess draining into a bronchus leads to reddish brown pus being coughed out.

Amoebic abscess of the brain may occasionally result from haematogenous spread from amoebic lesions in the colon or other sites. It causes severe destruction of brain tissue and is fatal. Abscesses in other organs such as spleen, kidney and suprarenal gland are rare and follow blood spread. Cutaneous amoebiasis occurs by direct extension around the anus, colostomy site or discharging sinuses from amoebic abscesses. Extensive gangrenous destruction of the skin occurs. The lesion may be mistaken for condylomata or epithelioma. The prepuce and glans are affected in penile amoebiasis which is acquired through anal intercourse. Similar lesions in females may occur on vulva, vaginal wall or cervix by spread from perineum. The destructive ulcerative lesions resemble carcinoma.

### **Laboratory Diagnosis**

Definitive diagnosis of amoebiasis depends on the demonstration of *E.histolytica* trophozoites or its cysts in stools, tissues or discharges from the lesions. Cultures are not employed for routine diagnosis. Immunological tests are not helpful for diagnosis of intestinal infection but may be of use in extraintestinal amoebiasis.

### ***Intestinal Amoebiasis***

**Acute amoebic dysentery:** The disease has to be differentiated from bacillary dysentery. The stool sample has to be collected directly into a wide mouthed container and examined without delay. Prior administration of antiamoebic drugs, bismuth, kaolin or mineral oil may interfere with demonstration of the trophozoite. It should be inspected for macroscopic and microscopic features, as well as routine examination for other parasites also. Examination of three separate samples is recommended.

a. **Macroscopic appearance:** The stool is copious, semiliquid, brownish black in colour and contains foul smelling faecal material intermingled with blood and mucus. It is acid in reaction. It does not adhere to the container.

b. **Microscopic appearance:** The cellular exudate is scanty and consists of a few pus cells, epithelial cells and macrophages. The red cells are aggregated and yellowish or brownish red in colour. Charcot-Leyden crystals are often present. But this finding is only suggestive, because they may also occur in some other bowel disorders such as ulcerative colitis and malignancy. In freshly passed motion unmixed with urine or antiseptics, actively motile trophozoites of *E.histolytica* can be demonstrated in unstained saline mounts. The presence of ingested erythrocytes clinches the identity of *E.histolytica*, as they are not found in any other intestinal amoeba. Stained films may not be necessary as a routine for diagnosis in acute cases, but trichrome or iron-haematoxylin stained films provide the most dependable identification and differentiation.



Culture and serology are not routinely employed. Serology is usually negative in early cases and in the absence of deep invasion.

### **Chronic Amoebiasis and Carriers**

Sigmoidoscopy may show amoebic ulcers in the colon, from which biopsy tissue may be taken for direct microscopy and histopathology. Identification of asymptomatic carriers is important in epidemiological survey and in screening persons employed in food handling occupations. In chronic patients, convalescents and carriers, besides naturally passed stools, it may be necessary to examine stools obtained after a saline purge for trophozoites and cysts. Excretion of amoeba is irregular and repeated stool examination is therefore necessary. The demonstration of cysts is facilitated by the use of a suitable concentration method such as the zinc sulphate centrifugal floatation technique. Examination of iodine and iron-haematoxylin stained preparations is helpful. Trophozoites, when present may be in the minuta form and may not have ingested erythrocytes. Differentiation from other amoebae may require the study of nuclear morphology after staining. Samples may be fixed with 10 per cent formalin, Schaudin's fixative or polyvinyl alcohol and stained with Gomorri trichrome or periodic acid Schiff stains. Cultures are not used routinely but may on occasion prove positive in cases found negative by microscopy. Cultures permit the determination of zymodeme patterns for differentiation between pathogenic and nonpathogenic strains. Serological tests may not be positive except in cases of invasive amoebiasis. Immunodetection tests for identifying *E.histolytica* antigens in clinical samples are available. Highly specific ELISA reagents can differentiate between *E.histolytica* and *E.dispar* antigens. Polyvalent immunochromatographic strip tests can detect amoeba, giardia and cryptosporidium antigens in stool samples.

**Extraintestinal (Invasive) Amoebiasis**

*Hepatic amoebiasis:* In diffuse hepatic amoebiasis (amoebic hepatitis) without localised abscess formation, laboratory diagnosis may be difficult. Often stool examination is negative for amoebae and a history of dysentery may be absent. In such cases serological tests can be helpful.

### **Extraintestinal (Invasive) Amoebiasis**

*Hepatic amoebiasis:* In diffuse hepatic amoebiasis (amoebic hepatitis) without localised abscess formation, laboratory diagnosis may be difficult. Often stool examination is negative for amoebae and a history of dysentery may be absent. In such cases serological tests can be helpful.

Craig (1928) was the first to report a complement fixation test in amoebiasis. Subsequently a number of different serological tests have been developed including indirect haemagglutination (IHA), latex agglutination (LA), gel diffusion precipitation (GDP), cellulose acetate membrane precipitation (CAP) test, counter current immunoelectrophoresis (CIE) and enzyme linked immunosorbent assay (ELISA). While IHA and LA are highly sensitive, they often give false-positive results. They remain positive for several years even after successful treatment. Gel precipitation tests are less sensitive, but more specific. ELISAs are both sensitive and specific and like GDP and CIE become negative within six months of successful treatment. Highly sensitive radioimmunoassay (RIA) and DNA probes have been introduced for detection of amoeba antigens in blood pus and faeces but these are too complex for routine use. In case of liver abscess when diagnostic aspiration is done the pus obtained from the centre of the abscess may not contain amoebae as they are confined to the periphery. The fluid draining after a day or two is more likely to contain the trophozoite.

Aspirates from the margins of the abscess also would show the trophozoites. Cysts are never seen in extraintestinal lesions.



### **Other Extraintestinal Amoebiasis**

In pulmonary amoebiasis the trophozoite may be seen in the expectorated anchovy sauce sputum. Cutaneous amoebiasis, and whenever accessible materials from other invasive lesions also show the trophozoites

### **Immunity**

Infection with invasive strains induces both humoral and cellular immune responses. Local and systemic antibodies can be demonstrated within a week of invasive infection. Infection confers some degree of protection as evidenced by the very low frequency of recurrence of invasive colitis and liver abscess in endemic areas. The course and severity of amoebiasis do not seem to be affected by HIV infection. Serological response is hardly ever seen in infection with noninvasive zymodemes.

### **Epidemiology**

Amoebiasis is worldwide in prevalence though it is more common in the tropical areas where sanitation is poor. Prevalence rates vary from as low as 1 per cent in affluent countries to more than 50 per cent in some developing countries. Some 500 million new infections occur each year worldwide. Infection occurs at all ages and in both sexes, though it is more common in adults than in children, and in males than in females. The source of infection is a carrier or asymptomatic cyst passer. The patient with acute dysentery is of no importance in transmission as the stools then contain only trophozoites which are not infective. Carriers may shed the infective cysts for years.

When cooks and other food handlers happen to be carriers they can transmit the infection readily. Amoebiasis in animals does not appear to be of any importance as a source of human infection. Amoebiasis is essentially an endemic disease though it can occasionally occur in epidemic form due to contamination of water sources. Contaminated food and water constitute the most important vehicles of infection. The cysts are relatively resistant. They can survive for several months in water at 0°C, 3 days at 30°C, 30 minutes at 40°C and 5 minutes at 50°C. In grossly contaminated water and sewage they may survive longer. They remain viable in moist soil for upto 10 days. They can resist 1/2500 mercury bichloride, 5 per cent HCl or 0.5 per cent formalin for 30 minutes and 1/500 potassium permanganate for 1 to 2 days.

They are killed by boiling, desiccation, freezing to below—5°C, 1/20 cresol in 30 minutes and 5 per cent acetic acid in 15 minutes. Ordinary residual chlorination of water may not destroy them, though super-chlorination does. Flies and cockroaches may act as mechanical vectors. Viable cysts have been found in their droppings for a day or two after exposure. Increased and varied male homosexual practices, particularly in the West, have enhanced the incidence of amoebiasis, which has been recognised as a 'gay bowel disease.'

### **Prophylaxis**

General prophylaxis is as for all faecal-oral infections. Food and water have to be protected from contamination with human excreta. Detection and treatment of carriers and their exclusion from food handling occupations limit the spread of infection. Health education and inculcation of healthy personal habits help in control.

### **Treatment**

Two classes of drugs are used in the treatment of amoebiasis—the luminal amoebicides (e.g. diloxanide furoate, iodoquinol, paromomycin, tetracycline) acting in the intestinal lumen, but not in tissues, and the tissue amoebicides (e.g. emetine, chloroquine) effective in systemic infection, but less so in the intestine. Metronidazole and related compounds act at both sites. Emetine, for long the sheet anchor in treatment of amoebiasis has largely been given up because of its toxicity. Opinion is divided about the need for treating asymptomatic cyst passers in endemic areas. It may perhaps be futile in view of the high rate of reinfection.

### ***PLASMODIUM FALCIPARUM***

The name falciparum comes from the characteristic sickle shape of the gametocytes of this species (*falx*-sickle, *parere*-to bring forth). This is the most highly pathogenic of all the plasmodia and hence the name malignant tertian or pernicious malaria for its infection. The disease has a high rate of complications and unless treated is often fatal. The species is responsible for almost all deaths caused by malaria. It is deeply entrenched in tropical Africa and some parts of Asia. It is limited to the tropical and subtropical regions because at temperatures below 20°C, its development in the mosquito is greatly retarded. This is the species of the greatest public health importance due to its increasing resistance to antimalarial drugs and its spread to new areas. In India, it has been spreading widely, causing large epidemics in some places.

The sporozoites are sickle-shaped. The tissue phase consists of only a single cycle of pre-erythrocytic schizogony. No hypnozoites occur. The mature liver schizont releases about 30,000 merozoites. They attack both young and mature erythrocytes and so the population of cells affected is very large. Infected erythrocytes present a brassy colouration.

The early ring form in the erythrocyte is very delicate and tiny, measuring only a sixth of the red cell diameter. Rings are often seen attached along the margin of the red cell, the so-called *form applique* or *accolé*. Binucleate rings are common resembling stereo headphones in appearance. Several rings may be seen within a single erythrocyte. In course of time, the rings become larger, about a third of the size of the red cell and may have one or two grains of pigment in its cytoplasm.

The subsequent stages of the asexual cycle—late trophozoite, early and mature schizonts—are not ordinarily seen in peripheral blood, except in very severe or pernicious malaria. The presence of *P.falciparum* schizonts in peripheral smears indicates a grave prognosis. The trophozoites usually disappear from peripheral circulation after about 24 hours. By then, a strain-specific high molecular weight antigen appears on the surface of the infected red cells, associated with knob-like projections on the erythrocyte membrane. Such red cells disappear from peripheral circulation and adhere to the walls of venules and capillaries in internal organs—brain, heart, kidney, lungs, spleen, intestine, bone marrow, placenta. This cytoadherence causes sequestration of infected red cells in these sites and is responsible for many of the serious complications of falciparum malaria, such as cerebral malaria. The mature schizont is smaller than in any other species and has 8 to 24 (usually 16) merozoites. The erythrocytic schizogony takes about 48 hours or less, so that the periodicity of febrile paroxysms is 36 to 48 hours. Very high intensity of parasitisation is seen in falciparum malaria. In very severe infections the rate of parasitised cells may even be up to 50 per cent. The infected erythrocytes are of normal size. They show a few (6-12) coarse brick-red dots which are called *Maurer's clefts*. Some red cells show basophilic stippling.

Gametogony begins after several generations of schizogony. Gametocytes are seen in circulation about 10 days after the ring stage first appears. The early gametocytes seldom appear in peripheral circulation. The mature gametocytes which are seen in peripheral smears are curved oblong structures variously described as crescentic, sickle, sausage or banana-shaped. They are usually referred to as crescents. The male gametocytes are broad and sausage-shaped or kidney-shaped; with blunt rounded ends as compared to the female gametocytes which are thinner and more typically crescentic, with sharply rounded or pointed ends. The mature gametocyte is longer than the diameter of the red cell and so produces gross distortion and sometimes even apparent disappearance of the infected red cell. The red cell is often seen as a rim on the concave side of the gametocyte. The cytoplasm in the female gametocyte is deep blue, while in the male it is pale blue or pink. The nucleus is deep red and compact in the female, with the pigment granules closely aggregated around it, while in the male it is pink, large and diffuse, with the pigment granules scattered in the cytoplasm. Falciparum crescents can survive in circulation for up to 60 days, much longer than in other

species. Gametocytes are most numerous in the blood of young children, 9 months to 2 years old. They therefore serve as the most effective source of infection to mosquitoes

### ***LEISHMANIA DONOVANI***

#### **History**

Sir William Leishman in 1900 observed the parasite in spleen smears of a soldier who had died of 'Dum Dum fever' or kala-azar contracted at Dum Dum, Calcutta. Leishman reported this finding from London in 1903, in which year Donovan also reported the same parasite in spleen smears of patients from Madras. The name *Leishmania donovani* was therefore given to this parasite. The amastigote forms of the parasite as seen in smears from patients, are called *Leishman-Donovan (LD) bodies*. *L. donovani* causes visceral leishmaniasis or kala-azar. It also causes the condition post-kala-azar dermal leishmaniasis (PKDL). Leishmaniasis is a major public health problem in many parts of the world. According to the WHO Report of 1990, 1.5 million cases of cutaneous leishmaniasis and 500,000 cases of visceral leishmaniasis occur every year, spread over 82 countries. About 350 million people are at risk of leishmaniasis, with 12 million people currently infected.

#### **Morphology and Life Cycle**

The parasite exists in two forms, the amastigote form in humans and other mammals, and the promastigote form in the sandfly and in artificial cultures. The amastigote form (LD body) is an ovoid or rounded cell, about 2 to 4  $\mu\text{m}$  in size. It is typically intracellular, being found inside macrophages, monocytes, neutrophils or endothelial cells. Smears stained with Leishman, Giemsa or Wright stains show a pale blue cytoplasm enclosed by a limiting membrane. The large oval or round nucleus is stained red. Lying at right angles to the nucleus is the red or purple stained kinetoplast. In well-stained preparations, the kinetoplast can be seen to consist of the parabasal body and a dot-like blepharoplast with a delicate thread connecting the two. The axoneme arising from the blepharoplast extends to the anterior tip of the cell. Alongside the kinetoplast can be seen a clear unstained vacuole. These are found mostly within the macrophages in the spleen, liver and bone marrow and less often in other locations such as the skin, intestinal mucosa and mesenteric lymph nodes. They multiply by binary fission, producing numerous daughter cells that distend the macrophage and rupture it. The liberated daughter cells are in turn phagocytosed by other macrophages and histiocytes. Small numbers of LD bodies can be found in peripheral blood inside polymorphonuclear leukocytes or monocytes. Rarely they may be seen in feces, urine and nasal secretions.

When a vector sandfly feeds on an infected person, the amastigotes present in peripheral blood and tissue fluids enter the insect along with its blood meal. In the midgut (stomach) of the sandfly, the amastigote elongates and develops into the promastigote form. The promastigotes, which are initially short oval or pear-shaped forms, subsequently become long spindle-shaped cells, 15 to 25  $\mu\text{m}$  long, carrying a single flagellum 15 to 30  $\mu\text{m}$  in length. Stained films show pale blue cytoplasm with a red nucleus in the centre. The kinetoplast lies transversely near the anterior end. Near the root of the flagellum is present a vacuole. As the flagellum extends anteriorly without curving back on the body, there is no undulating membrane. Promastigote forms which develop in artificial cultures have the same morphology as those in the sandfly.

The promastigotes multiply by longitudinal binary fission and reach enormous numbers. They may be seen as large rosettes with their flagella entangled. In the sandfly, they migrate from the midgut to the pharynx and hypostome, where they accumulate and block the passage. Such *blocked sandflies* have difficulty in sucking blood. When they bite a person and attempt to suck blood, plugs of adherent parasites may get dislodged from the pharynx and deposited in the punctured wound. The promastigotes so deposited are phagocytosed by macrophages inside which they change into amastigotes and start multiplying. These, in turn enter the midgut of a sandfly when it bites the infected person. It takes about 6 to 10 days after

ingestion of the amastigotes for the promastigotes to reach adequate numbers so as to block the buccal cavity and pharynx of the sandfly. This is, therefore, the duration of the extrinsic incubation period. This is also synchronous with the gonadotropic cycle of the vector so that amastigotes ingested during one blood meal, are ready to be transmitted when the sandfly takes the next blood meal, after its eggs have been laid.

### **Ecological Types**

The epidemiology and clinical features of visceral leishmaniasis and the ecology of the parasite are very different in different geographical areas. The different clinical syndromes have therefore been considered to be distinct entities and the parasites causing them have been given separate species or subspecies status, as listed below.

- i. Indian visceral leishmaniasis caused by *L.donovani* producing the anthroponotic disease kala-azar, and its sequel 'post-kala-azar dermal leishmaniasis' (PKDL). This disease is not zoonotic, humans being the only host and reservoir. Vector is the sandfly *Phlebotomus argentipes*. (In India, classical kala-azar has rarely been seen caused by *L.tropica*).
- ii. Mediterranean—Middle Eastern leishmaniasis caused by *L. donovani infantum* (or *L.infantum*) affecting mostly young children. It is a zoonotic disease, the reservoir being dogs or wild canines such as foxes, jackals, and wolves. Vectors are *P. perniciosus* and *P. ariasi*.
- iii. East African leishmaniasis caused by *L.d.archibaldi*. The disease is zoonotic, found mainly in rural areas. Reservoirs are dogs, mongoose and wild mammals. Vectors are *P. orientalis* and *P. martini*.
- iv. South American leishmaniasis caused by *L.d.chagasi* (*L.chagasi*). The disease is zoonotic. Foxes and wild canines are the reservoirs. Dogs act as the link between the reservoir hosts and humans. The main vector is the sandfly *Lutzomyia longipalpis*.
- v. In China, the disease resembles the Mediterranean type (*L. infantum*) in the North West and the Indian type (*L.donovani*) in the East.
- vi. American (New World) visceral leishmaniasis is caused by *L.chagasi*. It is present in most parts of Latin America and resembles the disease caused by *L.infantum*.

### **KALA-AZAR**

The disease visceral leishmaniasis was first characterised in India, where it was known under the names, kala-azar meaning black sickness), Dum Dum fever, Burdwan fever or tropical splenomegaly.

### **Clinical Features**

The infection is transmitted by the bite of the sandfly *P. argentipes*. Instances of transmission of the disease by blood transfusion, sexual contact, inoculation and congenitally have been recorded, but these are extremely rare and of no epidemiological significance. Most infections are inapparent or subclinical and only about 3 per cent develop the typical kala-azar syndrome. The incubation period is usually from 2 to 6 months, though occasionally it may be as short as 10 days or as long as two years. Cutaneous lesion at the site of bite of the sandfly is not seen in Indian patients, but is common in patients in Sudan and the Middle East. The onset is typically insidious. The clinical illness begins with fever, which may be continuous, remittant or irregular. Splenomegaly starts early and is progressive and massive. Hepatomegaly and lymphadenopathy also occur but are not so prominent. The disease progresses for several months, with periods of apyrexia followed again by fever. Emaciation and anaemia develop. The skin becomes dry, rough and darkly pigmented (hence the name kala-azar). The hair becomes thin and brittle. Epistaxis and bleeding gums are common. Most untreated patients die in about 2 years due to some intercurrent disease such as dysentery or tuberculosis. About 10 to 20 per cent of patients who recover develop post kala-azar dermal leishmaniasis (PKDL). The dermal lesions usually develop about a year or two after recovery from the systemic illness. The lesions are of 3 types—*depigmented macules* which appear commonly on the trunk and extremities, or *erythematous patches* appearing on the face (butterfly patch), both of which develop into



painless yellowish pink non-ulcerating *granulomatous nodules*. The parasite can be demonstrated in the lesions. PKDL is seen mainly in India. It is rare in East Africa and China and not seen elsewhere.

### **Pathology**

Kala-azar is a reticuloendotheliosis resulting from the invasion of the reticuloendothelial system by *L.donovani*. Parasitised macrophages disseminate the infection to all parts of the body. In the spleen, liver and bone marrow particularly, the amastigotes multiply enormously in the fixed macrophages to produce a 'blockade' of the reticuloendothelial system. This leads to a marked proliferation of the reticuloendothelial tissue in these organs. The spleen is the organ most affected. It is grossly enlarged and the capsule is frequently thickened due to perisplenitis. It is soft and friable and cuts easily without resistance, due to absence of fibrosis. The cut section is red or chocolate in colour due to the dilated and engorged vascular spaces. The trabeculae are thin and atrophic. Microscopically, the reticulum cells are greatly increased in numbers and are loaded with LD bodies. Lymphocytic infiltration is scanty, but plasma cells are numerous. The liver is enlarged. The Kupffer cells and vascular endothelial cells are heavily parasitised, but hepatocytes are not affected. Liver function is therefore not seriously affected, though prothrombin production is commonly decreased. The sinusoidal capillaries are dilated and engorged. Some degree of fatty degeneration is seen.

The cut surface may show a nutmeg appearance. The bone marrow is heavily infiltrated with parasitised macrophages which may crowd out the haemopoietic tissues. Peripheral lymph nodes and lymphoid tissues of the nasopharynx and intestine are hypertrophic due to infiltration with parasitized cells, though this is not frequently seen in Indian cases. Anaemia occurs as a result of infiltration of the bone marrow as well as by the increased destruction of erythrocytes due to hypersplenism. Autoantibodies to red cells may contribute to haemolysis. Leucopenia, with marked neutropenia, and thrombocytopenia are frequently seen. Polyclonal hypergammaglobulinaemia is a common finding.

### **Immunity**

The most important immunological feature in kala-azar is the marked suppression of cell mediated immunity to leishmanial antigens. This makes possible the unrestricted intracellular multiplication of the parasite. Cellular responses to tuberculin and other antigens are also suppressed and may be regained some 6 weeks after recovery from the disease.

In contrast, there is an overproduction of immunoglobulins, both specific antileishmania antibodies as well as polyclonal IgG and IgM immunoglobulins. Circulating immune complexes are demonstrable in serum. Complement activation occurs, but the antibodies do not appear to be relevant in defense against the parasites. Patients who have recovered from the infection are considered immune to reinfection. HIV infection heightens susceptibility to visceral leishmaniasis.

### **Laboratory Diagnosis**

Methods employed in laboratory diagnosis are as follows:

1. Demonstration of the parasite in materials obtained from patients, by:
  - a. microscopy.
  - b. culture.
  - c. animal inoculation.
2. Demonstration of antibodies or antigens by using:
  - a. specific leishmanial antigens; or
  - b. non-specific antigens.
3. Non-specific serum tests.
4. Absence of hypersensitivity to leishmanial antigen.
5. Contributory findings in clinical laboratory tests.



### 1. Demonstration of Parasites in Material Obtained from Patients

a. For microscopic demonstration of the parasite, the materials collected are:

- i. peripheral blood.
- ii. bone marrow, and
- iii. splenic aspirate.

i. **Peripheral blood** contains the amastigotes present inside circulating monocytes and less often in neutrophils, but the numbers are so scanty that a direct blood smear may not show them. Chances of detecting them are somewhat improved by examination of a thick blood film or of the leucocytic edge in a blood smear. It is best to examine buffy coat smears though even these are not often found positive. Buffy coat smears show a diurnal periodicity, more smears being positive when collected during the day than at night.

ii. **Bone marrow aspirate** is the most common diagnostic specimen collected. Generally the sternal marrow is aspirated by puncturing the sternum at the level of the 2nd or 3rd intercostal space, using a sternal puncture needle. This consists a short stout needle with a stylet. It has a movable guard which is fixed at 1 to 2 cm from the tip, depending on the thickness of the chest wall over the sternum. After disinfecting and anaesthetising the skin, the needle is introduced into the sternal marrow and about 0.5 ml of marrow fluid aspirated using a syringe. The puncture wound is sealed with celloidin or Tr. benzoin. Bone marrow samples can be obtained also by puncturing the iliac crest.

iii. **Spleen aspirates** are richer in parasites and so more valuable for diagnosis. But the procedure can sometimes cause dangerous bleeding and so should be done carefully and only when a marrow examination is inconclusive. To guard against bleeding, prothrombin time and platelet count should be checked before the procedure. The spleen should be palpable at least 3 cm below the costal margin. The spleen is penetrated with a 21-gauge needle attached to a 5 ml syringe and aspiration done by applying gentle suction.

**Lymph node aspirates** are not useful in the diagnosis of Indian kala-azar, though it is employed in visceral leishmaniasis in some other countries. The materials collected, as described above can be tested by microscopy, culture and animal inoculation.

a) For **microscopy**, smears are stained by Leishman, Giemsa or Wright stains and examined under the oil immersion objective. Amastigote parasites (LD bodies) can be seen within macrophages, often in large numbers.

b) **Cultures** are made on Novy-McNeal-Nicolle (NNN) medium. This is a rabbit blood agar slope having an overlay of Locke's solution with added antibiotics (penicillin, streptomycin, gentamicin) dispensed in screw capped bottles. The material is inoculated into the water of condensation and the culture incubated at 24°C for 7 days. The parasite grows as promastigotes and can be demonstrated by examining a drop of the fluid under high power objective using reduced condenser aperture or preferably, phase contrast illumination. Stained smears can also be examined. If negative, the culture is reincubated and examined weekly for 4 to 6 weeks. Schneider's liquid tissue culture medium with added foetal calf serum is also used for culture.

c) **Animal inoculation** is not used for routine diagnosis. When necessary, hamster is the animal employed. The materials are inoculated intraperitoneally, or intradermally into the skin of the nose and feet. The inoculated animals are kept at 23 to 26°C. In positive cases, the parasite can be demonstrated in smears taken from ulcers or nodules developing at the sites of cutaneous inoculation, or from the spleen. Animal inoculation is a very sensitive method, but takes several weeks to become positive.

## **2. Demonstration of Antibodies or Antigens**

- a. Specific leishmanial antigens prepared from cultures have been used in a number of tests to demonstrate specific antibodies. These tests include complement fixation, counter immunoelectrophoresis, immunofluorescence and ELISA tests. In kala-azar, the immunofluorescent antibody (IFA) titre usually rises to 64 or above and declines slowly after treatment, eventually becoming negative. The direct agglutination test for anti-leishmanial antibody has been found to be highly specific and sensitive for diagnosis of kala-azar. A specific immunochromatographic dipstick method for antibody has been developed using recombinant leishmanial antigens.
- b. Specific antigen detection tests have been developed by immunoblotting and PCR. Nonspecific (nonleishmanial) antigens for serological tests have been used for many decades. The antigen originally used was prepared from human tubercle bacillus by Witebsky, Klingenstein and Kuhn (hence called the WKK antigen). Complement fixation test with WKK antigen becomes positive early in the disease, within weeks of infection. Positive reaction also occurs in some other conditions, including tuberculosis, leprosy and tropical eosinophilia. An antigen prepared from Kedrowsky's acid-fast bacillus is preferred.
- c. *Nonspecific Serum Tests:* Some diagnostic tests for kala-azar are based on the greatly increased globulin content of serum in the disease. The two tests widely used are Napier's aldehyde or Formol gel test and Chopra's antimony test.
  - i. In Napier's aldehyde test 1 ml of clear serum from the patient is taken in a small test tube, a drop of formalin (40% formaldehyde) is added, shaken and kept in a rack at room temperature. A control tube with normal serum is also set up. A positive reaction is jellification and opacification of the test serum, resembling the coagulated white of egg, appearing within 3 to 30 minutes. About 85 per cent of patients with disease of 4 months or more give positive reaction.
  - ii. Chopra's antimony test is done by taking 0.2 ml of serum diluted 1 in 10 with distilled water, in a Dreyer's tube and overlaying with 4 per cent solution of urea stibamine in distilled water, run along the side of the tube. In a positive test, a thick flocculent disc forms at the junction of the two liquids in 10 to 15 minutes. This reaction is said to be more sensitive than the aldehyde test. Both tests give false-positive reactions in several other diseases, including tuberculosis and leprosy.

## **4. Absence of Hypersensitivity to Leishmanial Antigen**

A delayed hypersensitivity skin test, first introduced in South America by Montenegro, is known after his name. The Montenegro (leishmanin) skin test is negative in kala-azar. The test is done by injecting intradermally 0.1 ml of killed promastigote antigen. The test is read after 72 hours. It is positive in dermal leishmaniasis and in persons who have recovered from kala-azar, but not in active cases. In endemic areas, a number of healthy persons show a positive reaction, indicating prior exposure to the infection.

## **5. Contributory Findings in Clinical Laboratory Tests**

The following clinical laboratory tests give supportive evidence for the diagnosis of the disease. Blood examination shows a normocytic normochromic anaemia, leucopenia, neutropenia and thrombocytopenia. Serum globulin level is markedly elevated with reversal of albumen-globulin ratio.

### **Treatment**

Kala-azar responds to treatment better than other forms of visceral leishmaniasis. The standard treatment is the pentavalent antimonial sodium stibogluconate given intravenously 600 mg daily for 6 days. However, antimony resistance has become a serious problem. The aminoglycoside antibiotic amikacin (paromomycin) is useful, given alone or with antimonials. The dose is 14 mg/kg body weight daily given IM or as slow IV infusion once daily for 3 to 4 weeks. An alternative is pentamidine 4 mg/kg/day given IM for 10 days. If this also does not succeed, amphotericin 0.25 to 1 mg/kg/day may be given as slow infusion

for upto 8 weeks. By using liposomal amphotericin, higher doses can be given, improving the cure, without toxicity. Melfosine is an effective oral treatment.

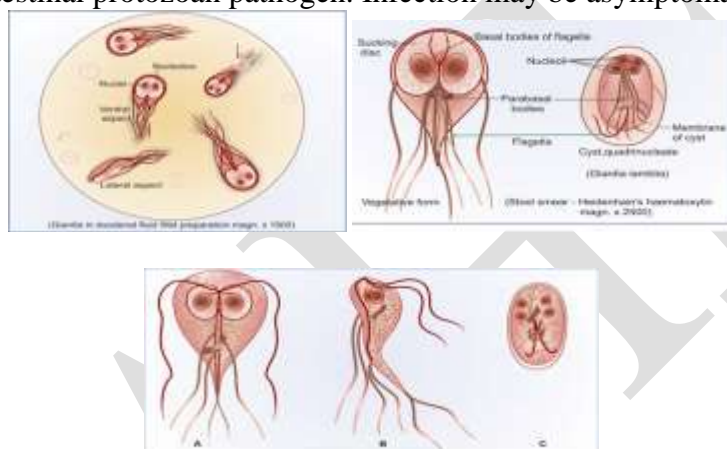
### Prevention

Prophylactic measures consist of treating all cases, eradication of the vector sandfly and personal prophylaxis by using antisandfly measures.

## GIARDIA INTESTINALIS

### History and Distribution

This flagellate was observed by Leeuwenhoek (1681) in his own stools and was thus one of the earliest of protozoan parasites to have been recorded. It is named Giardia after Professor Giard of Paris and lamblia after Professor Lambl of Prague who gave a detailed description of the parasite. Worldwide in distribution, it is the most common intestinal protozoan pathogen. Infection may be asymptomatic or cause diarrhoea.



**FIGURE:** *Giardia lamblia*. (A) Trophozoite—ventral view (B) Trophozoite—lateral view (C) Cyst

### Morphology and Life Cycle

*G. lamblia* lives in the duodenum and upper jejunum and is the only protozoan parasite found in the lumen of the human small intestine. It occurs in the vegetative and cystic forms. The vegetative form or *trophozoite* is rounded anteriorly and pointed posteriorly, about 15  $\mu\text{m}$  long, 9  $\mu\text{m}$  wide and 4  $\mu\text{m}$  thick. It has been described variously as pyriform, heart-shaped or racket-shaped. Dorsally it is convex and ventrally it has a concave *sucking disc* which occupies almost the entire anterior half of the body. It is bilaterally symmetrical and possesses 2 nuclei, one on either side of the midline, two *axostyles* running along the midline, 4 pairs of flagella and 2 sausage shaped *parabasal* or *median bodies* lying transversely posterior to the sucking disc. The trophozoite is motile, with a slow oscillation about its long axis, which has been likened to the motion of a 'falling leaf.' It divides by longitudinal binary fission. It lives in the duodenum and upper part of the jejunum attached by means of the sucking disc to the epithelial cells of the villi and crypts feeding by pinocytosis. Encystation occurs in the colon. The trophozoite retracts its flagella into the axonemes which remain as curved bristles in the cyst. The cyst is ovoid about 12  $\mu\text{m}$  by 8  $\mu\text{m}$  in size and surrounded by a tough hyaline cyst wall. The young cyst contains two and the mature cyst four nuclei situated at one end. Cysts are passed in stools and remain viable in soil and water for several weeks. There may be up to 2,00,000 cysts present per gram of faeces. In diarrhoeic stools trophozoites also may be present, but they die outside and are not infectious.

Infection is acquired by the ingestion of cysts in contaminated food and water. Infectivity is high, as few as 10 cysts being capable of initiating infection. Within half an hour of ingestion, the cyst hatches out into two

trophozoites which multiply successively by binary fission and colonise the duodenum. The trophozoites as they pass down the colon develop into cysts.

### **Pathogenesis and Clinical Features**

*G. lamblia* is seen typically within the crypts in the duodenum. It does not invade tissues, but remains tightly attached by means of the sucking disc to the epithelial surface in the duodenum and jejunum. This may cause abnormalities of villous architecture. Often no clinical illness results, but in some it may lead to mucus diarrhoea, dull epigastric pain and flatulence. The diarrhoea in some cases may be steatorrheic with excess mucus and fat, but no blood. Children may develop chronic diarrhoea, malabsorption, weight loss and a sprue-like syndrome. It has been suggested that enormous numbers of the parasite adhering to the mucosal surface of the small intestine may interfere with absorption. Increased bacterial colonisation of the small intestine has been observed in subjects with giardiasis and steatorrhea. Occasionally giardia may colonise the gallbladder, causing biliary colic and jaundice. The incubation period is variable, but is usually about 2 weeks.

### **Diagnosis**

The cysts and trophozoites can be found in diarrhoeal stools. Only the cysts are seen in asymptomatic carriers. Concentration by formalin ethyl acetate or zinc sulphate centrifugal floatation is useful when the cysts are sparse. Duodenal aspiration may sometimes be necessary to demonstrate the parasite in cases in which biliary symptoms predominate. A useful method for obtaining duodenal specimens is the *enterotest*, which uses a coiled thread inside a small weighted gelatin capsule. This is swallowed after attaching the free end of the thread to the cheek. The capsule passes through the stomach to the duodenum. After 2 hours, the thread is withdrawn, placed in saline and mechanically shaken. The centrifuged deposit of the saline is examined for giardia. ELISA and immunochromatographic strip tests have been developed for detection, of giardia antigens in faeces, but are not in routine use. Antibody demonstration is not useful in diagnosis.

### **Epidemiology**

The infection is worldwide, especially in children. Endemicity is very high in some areas. Visitors to such places, frequently develop traveller's diarrhoea caused by giardiasis, through contaminated water. Epidemics of giardiasis have been reported on a number of occasions. While ingestion of food and water contaminated with the cysts is the most common mode of infection, direct person-to-person transmission may also occur in children, male homosexuals and the mentally-ill. Enhanced susceptibility to giardiasis is associated with blood group A, achlorhydria, use of cannabis, chronic pancreatitis, malnutrition and immune defects such as 19A deficiency and hypogammaglobulinaemia. HIV infection has not apparently been associated with increased risk of giardiasis. Cats, dogs, cattle, sheep and many wild animals have been found naturally infected. While they are not considered to be responsible for human infection ordinarily, instances of giardiasis observed in some remote areas have been claimed to be due to water sources contaminated by such animals. *Giardia* species infecting birds, amphibians and mice can be differentiated from *G. lamblia* by morphological features.

### **Prophylaxis**

Prevention is as for other faecal-oral infections by better personal hygiene and prevention of food and water contamination. Iodine is effective in disinfecting drinking water.

### **Treatment**

Metronidazole and tinidazole are the drugs of choice. Furazolidone is slower in action, but is preferred in children as it has fewer adverse effects. Only symptomatic cases need treatment.



## **TRICHOMONAS VAGINALIS**

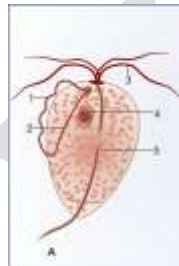
### **History**

*Trichomonas vaginalis* was first observed by Donne (1836) in vaginal secretion.

### **Morphology and Life Cycle**

*T. vaginalis* occurs only as the trophozoite, there being no cystic form in trichomonas. The trophozoite is ovoid or pear-shaped, about 10 to 30  $\mu\text{m}$  long and 5 to 10  $\mu\text{m}$  broad, with a short undulating membrane reaching up to the middle of the body. It has 4 anterior flagella and a fifth running along the outer margin of the undulating membrane, which is supported at its base by a flexible rod, the *costa*. A prominent *axostyle* runs throughout the length of the body and projects posteriorly. The cytoplasm shows prominent granules which are most numerous alongside the axostyle and costa.

It lives in the vagina and cervix in the female, and may also be found in the Bartholin's glands, urethra and even the urinary bladder. In males, it occurs mainly in the anterior urethra, but it may also be found in the prostate and preputial sac. It is motile, with a jerky rapid movement. It divides by binary fission. As cysts are not formed, the trophozoite itself is the infective form.



**FIGURE:** *Trichomonas vaginalis*. 1—Undulating membrane, 2—Costa, 3—Flagella, 4—Nucleus, 5—Axostyle

### **Culture**

It can be grown in a variety of solid and liquid media, in tissue culture and in eggs. CPLM (cysteine, peptone, liver, maltose) medium is often used.

### **Pathogenesis**

*T. vaginalis* infects selectively squamous and not columnar epithelium. Infection is often asymptomatic, particularly in the male. In females, it may produce severe pruritic vaginitis with an offensive, yellowish, often frothy discharge. Cervical erosion is common, with endometritis and pyosalpinx as infrequent complications. Dysuria in women is often due to trichomoniasis. Rarely neonatal pneumonia and conjunctivitis have been reported in infants born to infected mothers. In males it may produce urethritis (one type of nongonococcal urethritis). The incubation period is 4 days to 4 weeks.

### **Diagnosis**

The trichomonad may be found in sedimented urine and vaginal secretions, in wet films or Papanicolaou smears. Specimens collected on cotton swabs through a vaginal speculum and left for some time in a tube containing 5 per cent glucose saline show better shape and motility on examination. Prostatic massage may sometimes be necessary for detection of the parasite in males. Serological tests like indirect haemagglutination and gel diffusion are available for antibody detection.

### **Epidemiology**

*T. vaginalis* infection occurs worldwide, with an annual estimated incidence of 170 million. The trophozoite cannot survive outside the body and so infection has to be transmitted directly from person-to-person. Sexual transmission is the usual mode of infection. Trichomoniasis often coexists with other STDs—candidiasis, gonorrhoea, syphilis or HIV infection. Babies may get infected during birth. Fomites such as towels have been implicated in transmission. Prevention is as for other sexually transmitted diseases.



### **Treatment**

Metronidazole is the drug of choice. Simultaneous treatment of the sexual partner is necessary for cure.

## ***TOXOPLASMA GONDII***

### **History**

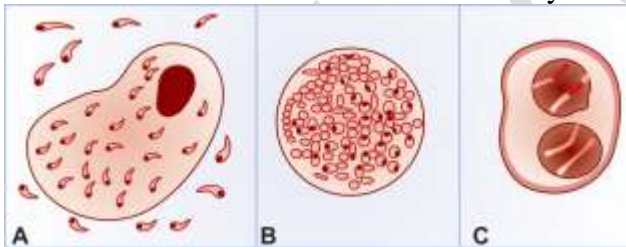
*Toxoplasma gondii* is an obligate intracellular coccidian parasite, first described in 1908 by Nicolle and Manceaux in spleen and liver smears of a small North African rodent called gundi, *Ctenodactylus gundi*. Its importance as a human pathogen was recognised only much later, when Janku in 1923 observed the cyst in the retina of a child with hydrocephalus and microphthalmia, Wolf and Cowen in 1937 identified the first congenital brain infection, and Pinkerton and Weinman recorded postnatal infection in 1940. With the discovery in 1948, of the Sabin-Feldman dye test, the first serological assay for toxoplasma antibody, the scope and extent of the infection became open for study.

The name toxoplasma is derived from the Greek word *Toxon* meaning arc or bow, referring to the curved shape of the trophozoite. Toxoplasmosis is now recognised as the most common protozoan parasite globally, with the widest range of hosts spread over 200 species of birds, reptiles and mammals, including humans. The life cycle of the parasite became clear only in 1970 when the domestic cat was identified as its definitive host, only in which it undergoes the sexual sporogony. All other species are merely intermediate hosts, in which only asexual schizogony takes place. Though human infection is very common, perhaps involving a third of the human race, clinical disease is relatively rare, being mostly opportunistic in nature.

### **Morphology**

*T. gondii* occurs in three forms—trophozoite, tissue cyst and oocyst.

The trophozoite and tissue cyst represent stages in asexual multiplication (schizogony), while the oocyst is formed by sexual reproduction (gametogony or sporogony). All three forms occur in the domestic cat and other felines which are the definitive hosts and which support both schizogony and gametogony. Only the asexual forms, trophozoites and tissue cysts are present in other animals, including humans, and birds, which are the intermediate hosts. Both oocysts and tissue cysts are infective by ingestion.

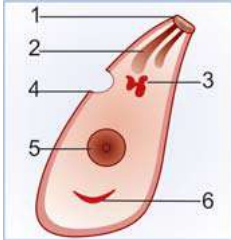


**FIGURE:** *Toxoplasma gondii*. (A) Smear from peritoneal fluid of infected mouse, showing crescentic tachyzoites—extracellular trophozoites and intracellular form within macrophage. (B) Thick-walled tissue cyst containing rounded forms (bradyzoites). (C) Oocyst containing two sporocysts with sporozoites inside

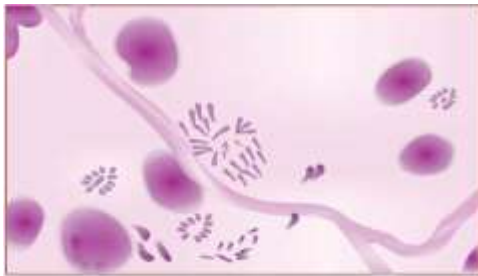### **Trophozoite**

The trophozoite is crescent-shaped, with one end pointed and the other end rounded. It measures approximately 3 µm by 7 µm. The nucleus is ovoid and situated near the blunt end of the parasite. Electron microscopy reveals an apical complex at the pointed end. The trophozoite stains well with Giemsa stain, the cytoplasm appearing azure blue and the nucleus red. It is seen intracellularly in various tissues and organs during the early acute phase of infection. Extracellular trophozoites can also be seen in impression smears. It can invade any nucleated cell and replicate within cytoplasmic vacuoles by a process called *endodyogeny* or *internal budding*—daughter trophozoites being formed, each surrounded by its own membrane, while still within the parent cell. When the host cell becomes distended with the parasites, it disintegrates releasing the trophozoites which infect other cells.

During acute infection, the proliferating trophozoites within a host cell may appear rounded and enclosed by the host cell membrane. This appearance, called the '*pseudocyst*' or '*colony*' can be differentiated from true tissue cysts by its staining reactions. The rapidly proliferating trophozoites in acute infection are called *tachyzoites*. Trophozoites can be propagated in the laboratory in eggs, tissue culture and in the peritoneum of mice, for maintenance of strains and preparation of antigens for serological tests. The trophozoites are susceptible to drying, freeze-thawing and to gastric digestion.



**FIGURE 6.2A:** *Toxoplasma gondii*. Trophozoite (tachyzoite), fine structure seen by electron microscopy. 1. Conoid, 2. Rhoptry 3. Golgi body 4. Cytostome 5. Nucleus 6. Mitochondrion



**FIGURE:** *T gondii*. Trophozoite grows in tissue culture. Smear shows trophozoites arranged in different patterns—singly, in cluster or as rosette (Giemsa stain)

### ***Tissue Cyst***

The tissue cyst is formed during the chronic phase of the infection and can be found in the muscles and various other tissues and organs, including the brain. The parasite multiplying slowly within the host cell, produces a cyst wall within the host cell membrane. The cyst wall is eosinophilic and stains with silver, in contrast to the '*pseudocyst*'. With periodic acid Schiff stain, the cyst wall stains weakly and the parasites inside deeply. The slowly multiplying parasites within the cyst are called *bradyzoites*. The cyst is round or oval, 10 to 200  $\mu\text{m}$  in size and contains numerous bradyzoites. Cysts remain viable in tissue for several years. In immunologically normal hosts, the cysts remain silent, but in the immunodeficient subjects they may get reactivated, leading to clinical disease. It is relatively resistant and when meat containing the cysts is eaten raw or undercooked, infection occurs. The cyst wall is disrupted by peptic or tryptic digestion and the released parasites initiate infection by invading intestinal epithelial cells. They reach various tissues and organs through blood and lymphatic dissemination. Cysts are susceptible to desiccation, freeze thawing and heat above 60°C.

### ***Oocyst***

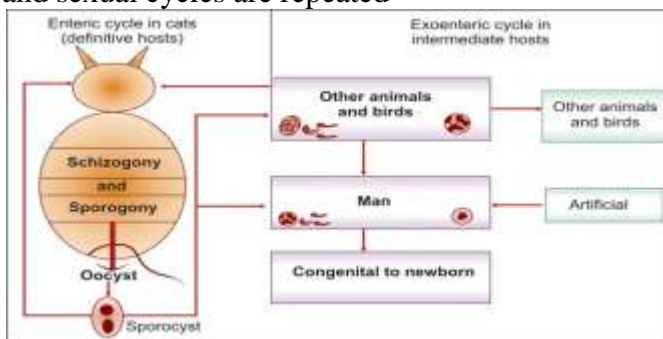
Oocysts develop only in definitive hosts—in the intestines of cats and other felines. When cats get infected by ingestion of either tissue cysts or oocysts, the parasites develop in the intestinal epithelial cells, where both schizogony and gametogony take place. Male and female gametocytes develop and after fertilisation, the zygote gets surrounded by a thin, but extremely resistant wall. This is the oocyst, which is spherical or ovoid about 10 to 12  $\mu\text{m}$  in size and contains a sporoblast. Cats shed millions of oocysts per day in faeces for about two weeks during the primary infection. The freshly passed oocyst is not infectious. It becomes

infectious only after development in soil or water for a few days. During this state of sporulation, the sporoblast divides into two sporocysts and four sporozoites develop inside each sporocyst. The mature oocyst containing eight sporozoites is the infective form. It is very resistant to environmental conditions and can remain infective in soil for about a year. When the infective oocyst is ingested, it releases sporozoites in the intestine, which initiate infection.

### Life Cycle

The life cycle of the parasite consists of 3 stages as follows—(a) Tachyzoites, the rapidly multiplying trophozoites which invade and multiply within cells, (b) bradyzoites, the slowly multiplying forms inside tissue cysts, seen during latent and chronic infection, and (c) sporozoites inside oocysts, which are shed in cat feces and remain in the environment.

In cats, which are the definitive hosts, both schizogony and gametogony take place in the epithelial cells of the small intestine. This is known as the *enteric cycle*. The oocysts produced by gametogony are shed in faeces. They develop into infective forms in soil or water. They may be ingested by felines to repeat the cycle. When ingested by other animals or birds which are intermediate hosts. The oocysts release sporozoites which infect the intestinal epithelial cells. Here, they multiply by endodyogeny to form tachyzoites. The host cell ruptures releasing numerous trophozoites which spread through blood and lymph infecting any type of nucleated cell in various tissues and organs. This is known as the *exoenteric cycle*. Primary infection with the parasite may be asymptomatic, acute or chronic. In chronic infections tissue cysts are produced within muscles and other tissues. When other intermediate hosts ingest these tissue cysts, the asexual cycle is repeated. When cats ingest the tissue cysts they become infected and in them both asexual and sexual cycles are repeated.



**FIGURE:** Life cycle of *Toxoplasma gondii*. Cats and other felines are the definitive hosts in which the enteric cycle takes place involving both schizogony (asexual) and sporogony (gametogony). Cat is infected either by ingestion of oocyst shed in its faeces or by eating flesh of other animals or birds containing tissue cysts. Oocysts shed in cat faeces sporulate, developing sporocysts containing sporozoites. When ingested these infect animals, humans and birds. Human infection also occurs from flesh of animals and birds containing tissue cysts. Artificial methods of human infection are laboratory contamination, blood transfusion and organ transplantation. Congenital infection also occurs.

Human infection is a dead end for the parasite. Human infection is obtained in the following ways—

- Eating uncooked or undercooked infected meat containing tissue cysts.
- Ingestion of mature oocysts through food, water or fingers contaminated with cat feces directly or indirectly.
- Intrauterine infection from infected mothers to babies.
- Rarely by blood transfusion or transplantation from infected donors.

### Clinical Features

Most human infections are asymptomatic. Clinical toxoplasmosis may be congenital or acquired.

### Congenital Toxoplasmosis

Congenital toxoplasmosis results when infection is transmitted transplacentally from mother to foetus. This occurs when the mother gets primary toxoplasma infection, whether clinical or asymptomatic during the pregnancy. The risk of foetal infection rises with the progress of gestation, from 25 per cent when the mother acquires primary infection in the first trimester, to 65 per cent in the third trimester. Conversely the severity of foetal damage is highest when infection is transmitted in early pregnancy. Mothers with chronic or latent Toxoplasma infection acquired earlier do not ordinarily infect their babies, but in some women with latent or chronic infection, the tissue cyst may be reactivated during pregnancy and liberate trophozoites which may reach the fetus *in utero*. Most infected newborns are asymptomatic at birth and may remain so throughout. Some develop clinical manifestations of toxoplasmosis weeks, months or even years after birth. The manifestations may be chorioretinitis, strabismus, blindness, deafness, epilepsy or mental retardation. A few are born with manifestations of acute toxoplasmosis, which may include fever, jaundice, diarrhoea, petechial rashes, hydrocephalus, microcephaly, cerebral calcifications, microphthalmia, cataract, glaucoma, chorioretinitis, optic atrophy, lymphadenitis, pneumonitis, myocarditis and hepatosplenomegaly.

#### ***Acquired Toxoplasmosis***

Infection acquired postnatally is mostly asymptomatic. Clinical toxoplasmosis may present in different forms. The most common manifestation of acute acquired toxoplasmosis is lymphadenopathy, the cervical lymph nodes being most frequently affected. Fever, headache, myalgia and splenomegaly are often present. The illness may resemble mild 'flu' or infectious mononucleosis and is self-limited, though the lymphadenopathy may persist. In some there may be a typhus-like exanthem, with pneumonitis, myocarditis and meningoencephalitis, which may be fatal. Another type of toxoplasmosis is ocular. Approximately 35 per cent of cases of chorioretinitis in the USA and Europe have been reported to be due to toxoplasmosis. While most of these follow congenital infection, it may sometimes be due to postnatal infection.

Some cases may be so severe as to require enucleation. Toxoplasmosis primarily involving the central nervous system is usually fatal and often found in AIDS. Toxoplasmosis is particularly severe in the immunodeficient, particularly in AIDS patients, whether it is due to reactivation of latent infection or to new acquisition of infection. In them brain involvement is common. Host defence against toxoplasma infection involves both humoral and cellular responses. Specific IgG antibody can lyse extracellular trophozoites. But activated T cells and natural killer cells appear to be more important in containing the infection and preventing clinical disease.

#### **Diagnosis**

Laboratory diagnosis may be made by microscopic demonstration of the parasite, by its isolation or by serological tests. Giemsa stained impression smears of lymph nodes, bone marrow, spleen or brain may occasionally show the trophozoites, which can be readily identified by their morphology. Tissue sections may show the cyst forms. Isolation may be intraperitoneally is made by injecting body fluids or ground tissues into cell cultures or immunosuppressed mice. Peritoneal fluid and spleen smears may show the trophozoites after 7 to 10 days. Serial blind passages may often be necessary for isolation. Sera of inoculated animals may also be tested for antibodies.

The most common method of laboratory diagnosis is by serology. Several serological tests are available. These include the Sabin-Feldman dye test, indirect immunofluorescence, indirect haemagglutination, complement fixation and ELISA. The Sabin-Feldman dye test is based on the specific inhibition by antibody of the staining of the trophozoite by alkaline methylene blue. Toxoplasma trophozoites propagated in mice peritoneal cavity are used. An accessory factor present in fresh normal serum is essential for the reaction. The highest dilution of the test serum which inhibits the staining is the titre. The test becomes positive within 1 to 2 weeks after infection, reaching titres of 1000 or more in 4 to 8 weeks and remaining positive at lower titres for years. Fluorescent antibody test results are similar. The CF test becomes positive only 3 to 8



weeks after infection rises in titre over the next 2 to 8 months and declines to low or undetectable levels within a year. The dye test was the first serological test for toxoplasmosis and remained the gold standard for many decades. But as the test required live toxoplasma, it could be done only in select laboratories. It is seldom done now because of its complexity and as better tests like ELISA are available. The standard test used now is ELISA, separately for IgM and IgG antibodies. The presence of IgM antibody in the absence of IgG denotes current infection; IgM antibody with high titre IgG suggests infection in the recent past; Negative IgM with positive IgG indicates past infection. This is subject to individual variation. In some cases IgM antibody may persist up to 18 months. Serial ELISA provides better information than a single test.

### **Epidemiology**

The infection is worldwide, being found wherever there are cats. Numerous species of mammals, reptiles and birds are naturally infected. The full natural cycle is maintained predominantly by cats and mice. The mice eat materials contaminated with oocysts shed by cats. Mice get infected and develop cysts in their tissues. When such mice are eaten by cats they get infected. Infected cats shed oocysts in faeces.

Besides this cycle, several others have been documented. Human toxoplasmosis is a zoonosis. It is acquired through food or water contaminated with mature oocysts or by ingestion of raw or undercooked meat containing tissue cysts. Pork and beef frequently have tissue cysts. Flies and cockroaches may act as mechanical vectors by contaminating food with oocysts from soil. Infection may be water borne when the source of water is contaminated with cat faeces. Rarely infection may be transmitted through blood or leucocyte transfusion or organ transplantation. Toxoplasmosis may also be acquired by laboratory infection. The incubation period is usually 1 to 3 weeks. The outcome of infection depends on the immune status of the infected person. Active progression of infection is more likely in immunocompromised individuals. Toxoplasmosis has acquired great importance as one of the major fatal complications in AIDS. The incidence of congenital toxoplasmosis is estimated at approximately 1 in 1000 live births. Because of the public health importance of congenital toxoplasmosis, serological surveys for toxoplasma antibodies are conducted in many advanced countries in women of childbearing age, antenatal women and newborns.

### **Prevention**

Eradication of toxoplasmosis appears unlikely because it is so widely disseminated in nature. But some simple measures may reduce the risk of infection. These include proper cooking of meat and washing of hands before eating to safeguard against soil contamination of fingers.

### **Treatment**

Combined treatment with pyrimethamine and sulphonamides or cotrimoxazole may lead to clinical cure, though the parasites may not be eliminated. Spiromycin and clindamycin have also been used. Treatment is effective only against trophozoites and not against cysts.

## ***PNEUMOCYSTIS CARINII***

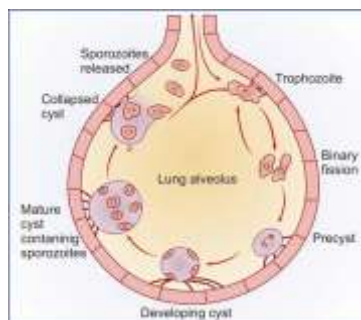
*Pneumocystis carinii* was first described by Chagas (1909) and Carini (1910) in the lungs of guinea pigs in Brazil. Human infection was recognised only in 1942 and subsequently several cases of interstitial pneumonia caused by the parasite have been observed, particularly in malnourished and premature infants. *P. carinii* has received much attention from the 1980s as it is one of the characteristic opportunistic infections seen in AIDS patients. It is far more commonly seen in AIDS patients in America and Europe than in Asia and Africa.

The taxonomic status of *P. carinii* has been uncertain. While it was generally considered as a sporozoan parasite, analysis of its chromosomal and mitochondria genes indicates its closer relationship to fungi than to protozoa. Natural infection with *P. carinii* occurs in many species of animals. It has been reported that

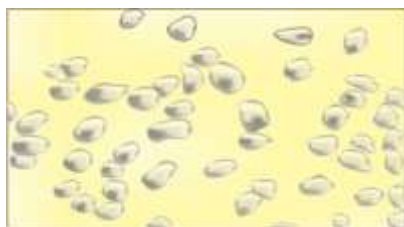

human infection may come from dogs or other domestic animals, but this is considered much less important than inter-human spread.

*P. carinii* lives within the alveoli of the lungs. It occurs in two forms, trophozoite and cyst. The trophozoite is 1 to 5  $\mu\text{m}$  in size, amoeboid in shape and has a central nucleus. Its cytoplasm contains mitochondria, ribosomes, endoplasmic reticulum and various granules. It divides by binary fission. Some trophozoites become encysted and produce within the cyst eight daughter trophozoites, also known as intracystic bodies or sporozoites. The mature cyst is thick-walled and measures up to 10  $\mu\text{m}$  in diameter. The cyst collapses, releasing trophozoites which initiate another cycle of multiplication, either in the same host, or in another if they have been spread by coughing. The collapsed cysts can be seen as irregular crescentic bodies.



**FIGURE:** lung in respiratory droplets and gets attached to alveolar epithelium. It divides by binary fission. Some form a thick-walled cyst within which sporozoites develop. When mature cysts rupture sporozoites are released which initiate fresh cycles of infection



**FIGURE :** *P. carinii* cyst (methanamine silver stain)

*P. carinii* is normally a commensal in the lung, spread by respiratory droplets. Many healthy persons have been reported to carry the organisms in the lungs. Pneumocystosis is an opportunistic infection, clinical disease being found only when the resistance is very low, as in premature and malnourished infants and in AIDS and other immunodeficiencies. The multiplication of the parasite in the lungs induces a hyaline or foamy alveolar exudate containing numerous lymphocytes, macrophages and plasma cells, but no polymorphs. In stained sections, the exudate filling the alveoli shows a characteristic honeycomb pattern. The disease presents with nonproductive cough, breathlessness and cyanosis. *P. carinii* pneumonia has been reported to be a very common life-threatening opportunistic infection in AIDS patients in the West.

Diagnosis may be made by demonstrating the parasite in sputum, tracheobronchial lavage or transbronchial biopsy specimens. Sputum examination is less satisfactory. Open lung biopsy may sometimes be necessary. Diagnosis is often made from autopsy specimens. The cysts can be stained by Giemsa or methanamine-silver techniques.

Immunofluorescence has been used for demonstrating cysts. *P. carinii* antigen can be demonstrated by ELISA. Cotrimoxazole and pentamidine have been used in treatment. But the prognosis is poor in pneumocystis pneumonia in the immunodeficient subjects.

### **BALANTIDIUM COLI**

*Balantidium coli* is a parasitic species of ciliate alveolates that causes the disease balantidiasis. It is the only member of the ciliate phylum known to be pathogenic to humans.

#### **Morphology**

*Balantidium coli* has two developmental stages, a trophozoite stage and a cyst stage. In trophozoites, the two nuclei are visible. The macronucleus is long and sausage-shaped, and the spherical micronucleus is nested next to it, often hidden by the macronucleus. The opening, known as the peristome, at the pointed anterior end leads to the cytostome, or the mouth. Cysts are smaller than trophozoites and are round and have a tough, heavy cyst wall made of one or two layers. Usually only the macronucleus and sometimes cilia and contractile vacuoles are visible in the cyst. Living trophozoites and cysts are yellowish or greenish in color.

#### **Role in disease**

*Balantidium coli* lives in the cecum and colon of humans, pigs, rats and other mammals. It is not readily transmissible from one species of host to another because it requires a period of time to adjust to the symbiotic flora of the new host. Once it has adapted to a host species, the protozoan can become a serious pathogen, especially in humans. Trophozoites multiply and encyst due to the dehydration of feces.

Infection occurs when the cysts are ingested, usually through contaminated food or water. *Balantidium* infection in immunocompetent individuals is not unheard of, but it rarely causes serious disease of the gastrointestinal tract. It can thrive in the gastrointestinal tract as long as there is a balance between the protozoan and the host without causing dysenteric symptoms. Infection most likely occurs in people with malnutrition due to the low stomach acidity or people with compromised immune systems.

In acute disease, explosive diarrhea may occur as often as every twenty minutes. Perforation of the colon may also occur in acute infections which can lead to life-threatening situations

#### **Life cycle**

Infection occurs when a host ingests a cyst, which usually happens during the consumption of contaminated water or food. Once the cyst is ingested, it passes through the host's digestive system. While the cyst receives some protection from degradation by the acidic environment of the stomach through the use of its outer wall, it is likely to be destroyed at a pH lower than 5, allowing it to survive easier in the stomachs of malnourished individuals who have less stomach acid. Once the cyst reaches the small intestine, trophozoites are produced. The trophozoites then colonize the large intestine, where they live in the lumen and feed on the intestinal flora. Some trophozoites invade the wall of the colon using proteolytic enzymes and multiply, and some of them return to the lumen. In the lumen trophozoites may disintegrate or undergo encystation. Encystation is triggered by dehydration of the intestinal contents and usually occurs in the distal large intestine, but may also occur outside of the host in feces. Now in its mature cyst form, cysts are released into the environment where they can go on to infect a new host.

#### **Epidemiology**

Balantidiasis in humans is common in the Philippines, but it can be found anywhere in the world, especially among those that are in close contact with swine. The disease is considered to be rare and occurs in less than 1% of the human population. The disease poses a problem mostly in developing countries, where water sources may be contaminated with swine or human feces

**Possible Questions**

**Part B (Two marks)**

1. What are types of flagellates? Write two example.
2. What is Hypnozoite?
3. Define exflagellation
4. What is Malarial Pigment?
5. List out the name of the Malarial Parasite.
6. Write a short note on Trichomonas.
7. Write few points about the morphology of *Giardia lamblia*.
8. What is meant by Schizogony, Sporogony, Merogony, Meront?
9. What are the stages involved in the life cycle of Malarial Parasite?

**Part B (Eight marks)**

1. Write about the ring form of malarial parasite.
2. Explain the pathogenecity of *Entamoeba histolytic*.
3. Explain the morphology and lifecycle of *Entamoeba histolytica* with a neat diagram?
4. Illustrate and Explain the morphology and life cycle of *Giardia lamblia*
5. Explain the life cycle of Malarial Parasite with a neat diagram?
6. Distinguish between the characteristics of Malarial parasite.
7. Illustrate and Explain the morphology of *Plasmodium falciparum*?
8. Explain the appearance of Malarial Pigments in different species.
9. Define the terms Malignant Tertian, Ovale Tertian, Quartan Malaria.
10. Explain the Pathogenecity of *Leishmania donavani*.
11. Illustrate the morphology of *Trichomonas vaginalis*.
12. Which protozoan is known as Malarial Parasite?
13. Write about the vectors which transmit the malarial parasite.
14. Explain the morphology and life cycle of *Toxoplasmosis gondii*.
15. Explain the morphology and life cycle of *Pneumocystis carinii*.

	Unit IV	Option 1	Option 2	Option 3	Option 4	Answer
1	Which plasmodial infection is more often associated with nephritic syndrome	P.vivax	P.malariae	P.falciparum	P.ovale	P.malariae
2	Anaemia produced is severest in	Falciparum malaria	Vivax malaria	Ovale malaria	Malariae malaria	Falciparum malaria
3	Which of the following is not true about falciparum malaria	Central nervous system involvement is maximum	Duration of primary disease is 2-3 weeks	Relapses are common	Periodicity of febrile paroxysms is 48 hours	Relapses are common
4	Merozoites produced per sporozoite in vivax malaria are about	2000	6000	10000	40000	10000
5	Relapse in case of vivax malaria results from reactivation of a dormant malaria parasite form which is known as	Hypnozoite	Sporozoite	Tachyzoite	Bradyzoite	Hypnozoite
6	Duration of untreated malarial infection is maximal in	Falciparum malaria	vivax malaria	Malariae malaria	Ovale malaria	Malariae malaria
7	Which of the following has not been reported from India	vivax malaria	Ovale malaria	Falciparum malaria	Malariae malaria	Ovale malaria
8	Which of the following has been classified as fungus recently	Isospora belli	Pneumocystis carinii	Dientamoeba fragilis	Cryptosporidium parvum	Pneumocystis carinii
9	Which of the following parasite has not been detected from brain	Acanthamoeba	Toxoplasma gondii	Entamoeba histolytica	Leishmania donovani	Leishmania donovani
10	Which of the following animal is most susceptible for isolation of Leishmania donovani	Hamster	Rabbit	Guinea pigs	Guinea worm	Hamster
11	Pneumonia is caused by ...	Pneumocystis	Trypanosoma	Ancylostome	Ascaris	Pneumocystis
12	Flagellates came under	Apicomplexa	Ciliphora	Aschelminthes	Sarcomastigophora	Sarcomastigophor

	phylum .....					a
13	Plasmodium is an example for .....	Sporozoans	Ciliates	Flagellates	Ameobas	Sporozoans
14	Dientamoeba is an example for .....	Ciliates	Flagellates	Ameobas	Worms	Flagellates
15	Plasmodium parasites exist within human host in the form of .....	Sporozoites / trophozoites	Ova	Cyst	unfertilised egg	Sporozoites / trophozoites
16	Quartan malaria is caused by	Plasmodium vivax	Plasmodium malariae	Plasmodium falciparum	Plasmodium ovale	Plasmodium malariae
17	Crescent shaped gametocytes are seen in infection with	Plasmodium falciparum	Plasmodium vivax	Plasmodium ovale	Plasmodium malariae	Plasmodium falciparum
18	Multiple rings per infected RBC are commonest in infections with:	Plasmodium falciparum	Plasmodium vivax	Plasmodium ovale	Plasmodium malariae	Plasmodium falciparum
19	Schizont stage of the parasite is not seen in the peripheral blood in infection with	Plasmodium falciparum	Plasmodium vivax	Plasmodium ovale	Plasmodium malariae	Plasmodium falciparum
20	Plasmodium falciparum ring stage can be confused with:	Babesiosis	LD bodies	Toxoplasma gon	Histoplasma caps	Babesiosis
21	Chagas' disease is usually treated with:	Nifurtimox	Niclosamide	Spraziquantel	Ivermectin	Nifurtimox
22	All the following drugs paralyse the worms except	Pyrantel pamoate	Plasmodium falciparum	Plasmodium malariae	Plasmodium ovale	Plasmodium ovale
23	All the following parasites can be encountered in the lungs except-----	Pneumocystis carinii	paragonium westermani	Echinococcus sp	Taenia solium	Pneumocystis carinii
24	Four nuclei are seen in the mature cyst of	Giardia	Entamoeba histolytica	Entamoeba coli	Plasmodium	Entamoeba histolytica
25	Trophozoite of Giardia has	2 axostyles	4 axo styles	3 axostyles	5 axostyles	5 axostyles
26	Cystic phase is absent in	T.vaginalis	T.vaginalis	T. tenax	Giardia lamblia	T.vaginalis
27	Single nucleus is seen in the trophozoite of	Giardia	Trichomonas	Plasmodium	Entamoeba histolytica	Trichomonas



28	Single nucleus is seen in the trophozoite of	Trichomonas	Entamoeba coli	Entamoeba histolytica	Giardia	Entamoeba histolytica
29	Sexually transmitted disease is caused by which flagellate?	T. vaginalis	T. hominis	T. tenax	Chilomastix mesnilli	T. vaginalis
30	Identify the flagellate which lives as a commensal in the oral cavity	T. vaginalis	T. tenax	T. hominis	Giardia	T. tenax
31	Motile reproductive stage of entamoeba histolytica is:	. trophozoite	Pre-cyst	cyst	Schizont	. trophozoite
32	Bundles of crystalline ribonucleic acid are	chromatoidal bodies	Karyosome	Periphearl chromatin	Pseudopodas	chromatoidal bodies
33	Pathogenic E. Histolytica strains are best distinguished from non-pathogenic ones by	Isoenzymes analysis	size of the cyst	No. of nucleoli in n	size of the trophozoite	Isoenzymes analysis
34	All the following have increased incidence of giardiasis except	pregnant woman	male homosexuals	children in day care centres	AIDS patients	pregnant woman
35	Which of the following parasites attaches to the small bowel mucosa with sucking disc	Entamoeba Histolytica	Giardia lamblia	Dientamoeba fragilis	Trichomonas vaginalis	Giardia lamblia
36	The drug commonly used to prevent pneumonia due to pneumocystis carinii in AIDS patients is	pentamidine isethionate	Niclosamide	Thiabendazole	Amphotericin	pentamidine isethionate
37	Approximately what percentage strains of E. histolytica are virulent	10%	30%	40%	50%	10%
38	Following intestinal infection, hepatic abscess is most likely to develop with	Entamoeba histolytica	Giardia la	Isospora belli	Chloroquine	Entamoeba histolytica
39	Leishmanial infections are usually treated with	Sodium stibogluconate	Metronidazole	Pentamidine	Chloroquine	Sodium stibogluconate

40	Dumdum fever or black poison is the name given to	Visceral leishmaniasis	Cerebral	Pneumocystis infection	Hepatic amoebiasis	Visceral leishmaniasis
41	Motile reproductive stage of entamoeba histolytica is	. trophozoite	Pre-cyst	cyst	Schizont	Trophozoite
42	Bundles of crystalline ribonucleic acid are	chromatoidal bodies	Karyosome	Periphearl chromatin	Pseudopodas	chromatoidal bodies
43	Pathogenic E. Histolytica strains are best distinguished from non-pathogenic ones by	Isoenzymes analysis	size of the cyst	No. of nucleoli in n	size of the trophozoite	Isoenzymes analysis
44	All the following have increased incidence of girardises except	pregnant woman	male homosexuals	children in day care centres	AIDS patients	pregnant woman
45	Which of the following parasites attaches to the small bowel mucosa with sucking disc	Entamoeba Histolytica	Giardia lamblia	Dientamoeba fragilis	Trichomonas vaginalis	Giardia lamblia
46	The drug commonly Used to prevent pneumonia due to pneumocystis carinii in AIDS patients is	pentamidine isethionate	Niclosamide	Thiabendazole	Amphotericin	pentamidine isethionate
47	Approximately what percentage strains of E.histolytica are virulent;	10%	30%	40%	50%	10%
48	Following intestinal infection, hepatic abscess is most likely to develop with	Entamoeba histolytica	Giardia la	Isospora belli	Chloroquine	Entamoeba histolytica
49	Leishmanial infections are usually treated with	Sodium stibogluconate	Metronidazole	Pentamidine	Chloroquine	Sodium stibogluconate
50	Dumdum fever or black poison is the name given to	Visceral leishmaniasis	Cerebral	Pneumocystis infection	Hepatic amoebiasis	Visceral leishmaniasis
51	Which of the following parasites get concentrated and are best detected in buffy coat blood film	Leishmania donovani	Giardia lamblia	Schistosoma	Wuchereria	Leishmania donovani

52	Identify the intestinal parasite	Entamoeba histolytica	Entamoeba gingivalis	Entamoeba Coli	Entamoeba nana	Entamoeba histolytica
53	Identify the commensal amoeba	Entamoeba Coli	Giardia lamblia	Leishmania brazil	Toxoplasma gon	Entamoeba Coli
54	Name the methods of reproduction seen in Entamoeba histolytica?	Excystation	Emasculation	Elimination	Expellation	Excystation
55	Which is / are the medium/ media used to cultivate Entamoeba histolytica ?	Boeck and Drbohlav medium	Nutrient agar	Cetrimide medium	Cary blair medium	Boeck and Drbohlav medium
56	Nucleus of Entamoeba coli has	Central karyosome	Peripheral or eccentric karyosomes	Peripheral or eccentric karyosomes	Many karyosomes	Peripheral or eccentric karyo
57	Identify the commensal amoeba living in the mouth	Entamoeba gingivalis	Entamoeba histolytica	Entamoeba coli	Entamoeba nana	Entamoeba gingivalis
58	Giardia interferes with the absorption of	Fat	Carbohydrate	Protein	Amino acid	Fat
59	Steatorrhoea is produced by	Giardia lamblia	Entamoeba coli	Entamoeba histolytica	Plasmodium	Giardia lamblia
60	The ineffective stage of entamoeba histolytica is	. trophozoite	Pre-cyst	cyst	Schizont	cyst

**UNIT-V**  
**SYLLABUS**

Helminthic infections – *Taenia solium*, *Trematodes* - *Schistosoma haematobium*, Nematodes - *Trichuris trichiura* - *Ascaris lumbricoides*, *Ancylostoma duodenale*, *Wuchereria bancrofti*.

**Helminthic Infection**

Helminths are bilaterally symmetrical metazoa belonging to the Phylum-Scolecida. The term “helminth” (Greek *helmins*-‘worm’) originally referred to intestinal worms, but now comprises many other worms, including tissue parasites as well as many free-living species.

Helminths have an outer protective covering, the cuticle or integument which may be tough and armed with spines or hooks. The mouth may be provided with teeth or cutting plates. Many helminths possess suckers or hooks for attachment to host tissues. The cuticle of live helminths is resistant to intestinal digestion. They do not possess organs of locomotion, but in some species the suckers assist in movement. Locomotion is generally by muscular contraction and relaxation.

Helminths do not possess a true coelomic or body cavity. In some parasitic helminths the digestive system is absent or rudimentary as they depend on pre-digested nutrients available from the host. Many helminths have a primitive nervous system. The excretory system is better developed. The greatest development is seen in the reproductive system. Helminths may be *monoecious* (with functioning male and female sex organs in the same individual) or *diecious* (the two sexes, male and female, separate). In the hermaphroditic helminths both male and female reproductive systems are present in the same worm and self-fertilisation as well as cross-fertilisation take place. In the diecious species males and females are separate, the male being smaller than the female. Rarely the female is parthenogenic, being able to produce fertile eggs or larvae without mating with males.

The eggs or larvae are produced in enormous numbers—as many as 200,000 or more per female per day. This seemingly wasteful excess is necessary as only few of them survive and manage to infect a suitable host. It has been estimated that their chance of survival and subsequent infection may be less than one in a million. Survival and development are further complicated by the fact that many helminths require more than one intermediate host for completion of their life cycle. The process of development in some helminths is extremely complex and is influenced by various factors such as environmental conditions and human customs and practices. Helminths differ from protozoa in their inability to multiply in the body of the host. Protozoa multiply in the infected person so that disease could result from a single infection. But helminths apart from very rare exceptions do not multiply in the human body so that a single infection does not generally lead to disease. Heavy worm load follows multiple infections.

**TAENIA SOLIUM**

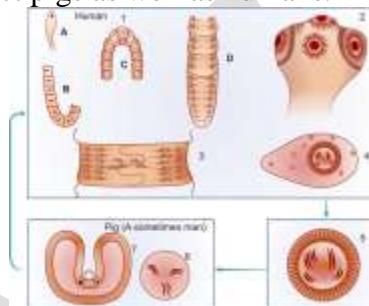
**History and Distribution**

Commonly called the *pork tapeworm*, this has been known from the time of Hippocrates. However, it was differentiated from the beef tapeworm only by Kuchenmeister (1855) and Leuckart (1956) who worked out its life cycle and demonstrated the larval stage in the pig. Kuchenmeister fed a condemned prisoner with 20 cysticercus cellulosae from a pig and when the criminal was executed four months later, 19 adult *T. Solium* were recovered from his intestines. Various derivations have been proposed for the name ‘solium’—from the Latin solus meaning solitary because usually only a single worm is found in infected persons, or sol meaning sun from a fancied resemblance of the rostellum with hooks to the sun and its rays, and from a Syrian word meaning a ‘chain’. *T. solium* is worldwide in distribution, except in the countries and communities which proscribe pork as taboo.

### Morphology and Life Cycle

The adult worm lives in the human intestine, usually in the jejunum, where it lies in several folds in the lumen. Commonly only a single worm is present, but rarely several worms may be seen, upto 25 or more in a patient. The adult worm is usually 2 to 3 metres long. The scolex is roughly quadrate about 1 mm in diameter, with 4 large cup-like suckers (0.5 mm in diameter) and a conspicuous rounded rostellum, armed with a double row of alternating round and small dagger-shaped hooks, 20 to 50 in number. The neck is short and half as thick as the head. The proglottides number less than a thousand. They resemble those of *T. Saginata* in general. The gravid segments are twice as long as broad, 12 mm by 6 mm. The testes are composed of 150 to 200 follicles. There is an accessory lobe for the ovary.

The vaginal sphincter is absent. The uterus has only 5 to 10 (under 13) thick lateral branches. A lateral thick-lipped genital pore is present, alternating between the right and left sides of adjacent segments. The gravid segments are not expelled singly, but pass passively out as short chains. The eggs escape from the ruptured wall of the uterus. The eggs are indistinguishable from those of *T. saginata*. They remain infective for several weeks in soil. They can infect pigs as well as humans.



**FIGURE:** Life cycle of *Taenia solium*. 1. Adult worm in human small intestine. A. Scolex and neck. B. Immature segments. C.

Mature segments, showing genital pore opening laterally alternating between right and left. D. Gravid segments. 2. Scolex bearing four suckers and a rostellum with a double row of hooks. 3. Mature segment longer than broad. Uterus has few branches.

(5-10). 4. Immature egg with hyaline embryonic membrane around it. 5. Mature egg deposited in soil, ingested by pig, or occasionally by man. 6. Oncosphere penetrates intestinal wall. 7. Cysticercus cellulosa develops in muscle (measly pork), the infective stage for humans

When the eggs are ingested by pig or humans, the embryos are released in the duodenum or jejunum. The oncospheres penetrate the intestinal wall, enter the mesenteric venules or lymphatics and are carried in systemic circulation to the different parts of the body. They are filtered out principally in the muscles where they develop into the larval stage, *cysticercus cellulosa* in about 60 to 70 days. The cysticercus cellulosa or 'bladder worm' is an ovoid opalescent milky-white bladder or vesicle surrounded by a fibrous capsule. It contains a thick fluid, rich in protein and salt. The scolex of the larva, with its suckers, lies invaginated within the bladder and can be seen as a thick white spot. It remains viable for several months. The cysticercus measures usually about 5 mm by 10 mm, but can be much larger when it occurs in the brain or subarachnoid space.

*Cysticercus cellulosa* can develop in humans or pigs. In humans it is a dead end and the larvae die without further development. When pork containing *cysticercus cellulosa* (measly pork) is consumed inadequately cooked, the larvae are digested out of the meat in the stomach and duodenum. The head evaginates out of the bladder and becomes attached to the jejunal mucosa. In 5-12 weeks it develops into a mature worm. *T. solium* has a long lifespan of about 25 years or more.





**FIGURE:** *T. solium* hooks

### **Pathogenesis**

The adult worms do not cause any disturbance apart from vague abdominal discomfort, indigestion or alternating diarrhoea and constipation. It is the larval stage that can cause serious trouble. Cysticercus cellulosae develop in humans following ingestion of *T. solium* eggs in water or vegetables. In persons harbouring the adult worm in the intestine, autoinfection and infection of close contacts can take place by finger contamination with eggs from the perineal skin or faeces. Autoinfection can also occur by the gravid segments reaching the stomach by retrograde peristalsis from the jejunum, whereupon they are digested and thousands of eggs released. Cysticercus cellulosae may be solitary or more often multiple, commonly numerous.

Any organ or tissue may be involved, the most common being subcutaneous tissues and muscles. It may also affect the eyes, brain, and less often the heart, liver, lungs, abdominal cavity and spinal cord. The symptomatology depends on the site affected. The cysticercus is surrounded by a fibrous capsule except in the eye and ventricles on the brain. The larvae evoke a cellular reaction starting with infiltration of neutrophils, eosinophils, lymphocytes, plasma cells and at times giant cells. This is followed by fibrosis and death of the larva with eventual calcification. In cysticercosis of the brain, symptoms are more often due to the dead and calcified larvae than the living larvae. Epilepsy is the most common manifestation, but it can also cause behavioural disorders, pareses or hydrocephalus. Ocular cysticercosis may cause blurring of vision, uveitis, iritis and ultimately blindness.

### **Epidemiology**

Intestinal infection with *T. solium* occurs only in persons eating undercooked pork and so is related to food habits. It is therefore absent in those with religious or other reservations against eating pork. But cysticercosis may occur in any person residing in endemic areas, even in vegetarians because the mode of infection is contamination of food or drink with eggs deposited in soil.

### **Diagnosis**

Infection with the adult worm is diagnosed by demonstration of eggs, or more specifically of proglottides in faeces. It can be differentiated from *T. saginata* on the characteristics of the proglottides. Definitive diagnosis of cysticercosis is by biopsy of the lesion and its microscopic examination to show the invaginated scolex with suckers and hooks. Cysticercosis in the subcutaneous tissue and muscles, particularly in the buttocks and thighs can be made out by radiological demonstration of the calcified larvae. Radiography is helpful for diagnosis of cerebral cysticercosis also, but CT scan is much more useful. Ocular cysticercosis can be made out by ophthalmoscopy. Eosinophilia usually occurs during the early stage of cysticercosis, but is not constant. An indirect haemagglutination test has been reported using an antigen obtained from cysticercus from pigs.

### **Treatment**

Praziquantel and niclosamide are useful in treatment of infection with the adult worm. For cysticercosis excision is the best method wherever possible. Praziquantel and metrifonate have been reported to be effective in cysticercosis.

### **Prevention**

Proper meat inspection in slaughter houses to eliminate measly pork, adequate cooking of pork, clean personal habits and general sanitary measures can prevent the infection. For control of cysticercosis, prevention of faecal contamination of soil, proper disposal of sewage and avoiding raw vegetables grown in polluted soil are useful measures. It is important to detect and treat persons harbouring adult worms as they can develop cysticercosis due to autoinfection.

### **TREMATODES - *SCHISTOSOMA HAEMATOBIIUM***

#### **History**

This vesical blood fluke, formerly known as *Bilharzia haematobium* has been endemic in the Nile valley in Egypt for millenia. Its eggs have been found in the renal pelvis of an Egyptian mummy dating from 1250-1000 B.C. Schistosome antigens have been identified by ELISA in Egyptian mummies of the Predynastic period, 3100 B.C. The adult worm was described in 1851 by Bilharz in Cairo. Its life cycle, including the larval stage in the snail was worked out by Leiper in 1915 in Egypt.

#### **Geographical Distribution**

Although maximally entrenched in the Nile valley, *S. haematobium* is also endemic in most parts of Africa and in West Asia. An isolated focus of endemicity in India was identified in Ratnagiri, south of Mumbai by Gadgil and Shah in 1952.

#### **Morphology and Life Cycle**

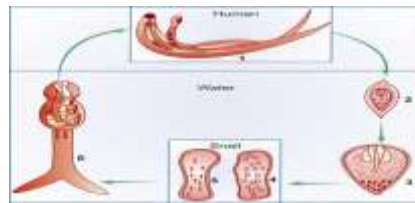
The adult worms live in the vesical and pelvic plexuses of veins. The male is 10 to 15 mm long by 1 mm thick and covered by a finely tuberculated cuticle. It has two muscular suckers, the oral sucker being small and the ventral sucker large and prominent. Beginning immediately behind the ventral sucker and extending to the caudal end is the gynaecophoric canal in which the female worm is held. The adult female is long and slender, 20 mm by 0.25 mm with the cuticular tubercles confined to the two ends.

The gravid worm contains 20 to 30 eggs in its uterus at any one time and may pass up to 300 eggs a day. The eggs are ovoid, about 150 µm by 50 µm, with a brownish yellow transparent shell carrying a terminal spine at one pole (the *terminal spine* is characteristic of the species). The eggs are laid usually in the small venules of the vesical and pelvic plexuses, though sometimes they are laid in the mesenteric portal system, pulmonary arterioles and other ectopic sites. The eggs are laid one behind the other with the spine pointing posteriorly. From the venules, the eggs make their way through the vesical wall by the piercing action of the spine, assisted by the mounting pressure within the venules and a lytic substance released by the eggs. The eggs pass into the lumen of the urinary bladder together with some extravasated blood. The eggs are discharged in the urine, particularly towards the end of micturition. For some unknown reasons, the eggs are passed in urine more during midday than at any other time of the day or night. The eggs laid in ectopic sites generally die and evoke local tissue reactions. They may be found, for instance in rectal biopsies, but are seldom passed live in feces.

The eggs that are passed in water hatch, releasing the ciliated miracidia. They swim about in water and on encountering a suitable intermediate host, penetrate into its tissues and reach its liver. The intermediate hosts are snails of *Bulinus* species in Africa. In India, the intermediate host is the limpet *Ferrisia tenuis*. Inside the snail, the miracidia lose their cilia and in about 4 to 8 weeks, successively pass through the stages of the first and second generation sporocysts. Large number of cercariae are produced by asexual reproduction within the second generation sporocyst. The cercaria has an elongated ovoid body and forked tail (*furcocercous*

*cercaria*). Swarms of cercariae swim about in water for 1 to 3 days. If during that period they come into contact with persons bathing or wading in the water, they penetrate through their unbroken skin. Skin penetration is facilitated by lytic substances secreted by penetration glands present in the cercaria.

On entering the skin, the cercariae shed their tails and become *schistosomulae* which enter the peripheral venules. They then start a long migration, through the vena cava into the right heart, the pulmonary circulation, the left heart and the systemic circulation, ultimately reaching the liver. In the intrahepatic portal veins, the schistosomulae grow and become sexually differentiated adolescents about 20 days after skin penetration. They then start migrating against the blood stream into the inferior mesenteric veins, ultimately reaching the vesical and pelvic venous plexuses where they mature, mate and begin laying eggs. Eggs start appearing in urine usually 10 to 12 weeks after cercarial penetration. The adult worms may live for 20 to 30 years. Humans are the only natural definitive hosts. No animal reservoir is known.



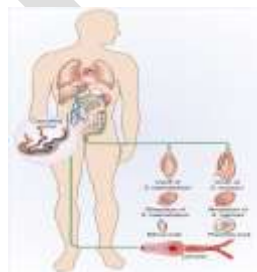**FIGURE:** Life cycle of *Schistosoma haematobium*. 1. Adult male and female in copula in the vesical venous plexus. 2. Egg containing ciliated embryo passed in urine reaches water. 3. Miracidium hatches out of egg and enters the snail liver. 4. Development in snail—Sporocyst first generation. 5. Sporocyst second generation. 6. Cercaria with forked tail released into water. Human infection by skin penetration

### Pathogenicity and Clinical Features

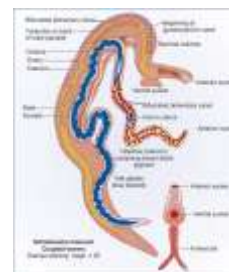Clinical illness caused by schistosomes can be classified depending on the stages in the evolution of the infection, as follows:

- i. Skin penetration and incubation period;
- ii. Egg deposition and extrusion; and
- iii. Tissue proliferation and repair.

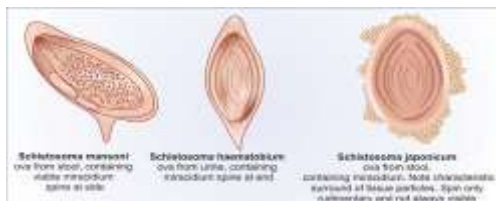
The clinical features during the incubation period may be local cercarial dermatitis or general anaphylactic or toxic symptoms. Cercarial dermatitis consists of transient itching petechial lesions at the site of entry of the cercariae. This is seen more often in visitors to endemic areas than in locals who may be immune due to repeated contacts. It is particularly severe when infection occurs with cercariae of nonhumans schistosomes. Anaphylactic or toxic symptoms include fever, headache, malaise and urticaria. This is accompanied by leucocytosis, eosinophilia, enlarged tender liver and a palpable spleen. This condition is more common in infection with *S. Japonicum* (*Katayama fever*). The typical manifestation caused by egg laying and extrusion is painless terminal haematuria (*endemic haematuria*). Haematuria is initially microscopic, but becomes gross if infection is heavy. Most patients develop frequency of micturition and burning.



**FIGURE:** *S. haematobium*: developmental stages



**FIGURE:** Schistosoma in coupled



Cystoscopy shows hyperplasia and inflammation of bladder mucosa with minute papular or vesicular lesions. In the chronic stage there is generalised hyperplasia and fibrosis of the vesical mucosa with a granular appearance (*Sandy patch*). At the sites of deposition of the eggs, dense infiltration with lymphocytes, plasma cells and eosinophils leads to pseudoabscesses. Initially the trigone is involved, but ultimately the entire mucosa becomes inflamed, thickened and ulcerated. Secondary bacterial infection leads to chronic cystitis. Calculi form in the bladder due to deposition of oxalate and uric acid crystals around the eggs and blood clots. There may be obstructive hyperplasia of the ureters and urethra. Schistosomiasis favours urinary carriage of typhoid bacilli. Chronic schistosomiasis has been associated with bladder cancer, though a causative relationship is not proved.

### **Diagnosis**

The eggs with characteristic terminal spines can be demonstrated by microscopic examination of centrifuged deposits of urine. Eggs are more abundant in the blood and pus passed by patients at the end of micturition. They can also be seen in seminal fluid. They may occasionally be found in feces, or more often in vesical or rectal biopsies. A refinement of diagnosis by demonstration of eggs is to hatch shed eggs into motile miracidia. Another diagnostic method is by detection of specific schistosome antigens in serum or urine. Two glycoprotein antigens associated with the gut of adult schistosomes (circulating anodic and cathodic antigens, CAA and CCA) can be demonstrated by ELISA using monoclonal antibodies. The test is very sensitive and specific, but is available only in specialised laboratories. Skin tests are group specific and give positive results in all schistosomiasis. The intradermal allergic test (Fairley's test) uses antigen from infected snails, from cercariae, eggs and adult schistosomes from experimentally infected laboratory animals. Several serological tests have been described but are not very useful. These include complement fixation, bentonite flocculation, indirect haemagglutination, immunofluorescence, gel diffusion and ELISA. Two special tests are circumoval precipitation (globular or segmented precipitation around schistosome eggs incubated in positive sera) and "cercarien-hullen" reaction (development of pericercarial membranes around cercariae incubated in positive sera). Animal schistosomes can be used as antigens in these tests. Ultrasonography is useful in diagnosing *S. haematobium* infection.

### **Treatment**

Metrifonate is the drug of choice in schistosomiasis due to *haematobium*. Praziquantel is effective against all schistosomes and also against many other trematode and cestode infections.

### **Prevention and Control**

Prophylactic measures include eradication of the intermediate molluscan hosts, prevention of environmental pollution with urine and feces and effective treatment of infected persons.

## **NEMATODES - *TRICHURIS TRICHIURA***

### **History and Distribution**

*Trichuris trichiura*, the human whipworm was first described by Linnaeus in 1771. It is worldwide in distribution, but is much more common in the tropics. Some 750 million people are estimated to be infected with this worm. While whipworm infection is extremely frequent, whipworm disease is relatively rare. The

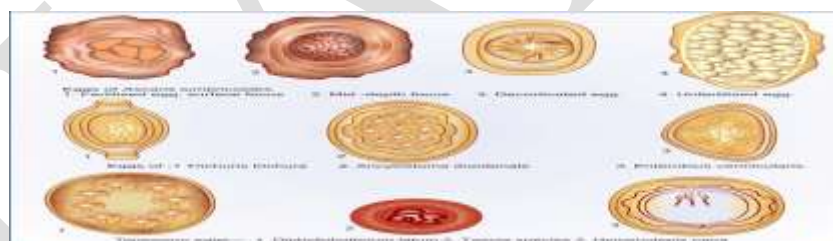


name *Trichuris* means a hair-like tail (Greek *trichos*—hair, *oura*—tail). This name is not quite correct because it is the anterior end that is hair-like, and not the tail. The name *whipworm* is more apt as the thick posterior part resembles the stock and the thin anterior the lash of a whip.

The antiquity of the whipworm as a human parasite is indicated by the demonstration of its eggs in colonic contents of a young man who died on the Alps some 5300 years ago and whose well-preserved body was discovered in 1990. The adult worms are found attached to the wall of the caecum and appendix. The male is 30 mm to 45 mm long, while the female is slightly larger, about 40 mm to 50 mm. The worm is flesh coloured. In shape it resembles a whip, with the anterior three-fifth thin and thread-like, and the posterior two-fifth thick and fleshy, appearing like the handle of a whip. The attenuated anterior portion which contains the capillary oesophagus, is embedded in the mucosa. The posterior part contains the intestines and reproductive organs. The posterior end of the male is coiled ventrally, while the hind end of the female is straight, blunt and rounded. The worm has a lifespan of 5 to 10 years.

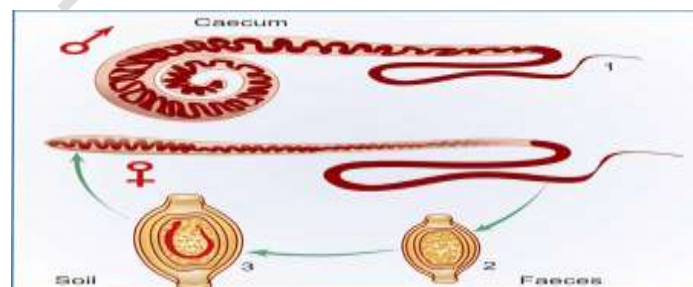
The fertilised female lays about 5000 eggs per day. The egg has a characteristic appearance. It is brown, being bile stained. It has a triple shell, the outermost layer of which is stained brown. It is barrel-shaped, about 50 µm long and 25 µm wide in the middle, with a projecting mucous plug at each pole. The egg floats in saturated salt solution. The egg passed in feces contains an unsegmented ovum. At this stage it is not infective for humans. The egg undergoes development in soil, optimally under warm, moist, shady conditions, when the infective rhabditiform larva develops within the egg in 3 to 4 weeks. At lower temperatures this may be delayed for 3 months or more.

Infection occurs when the mature embryonated eggs containing the infective larvae are swallowed in food or water. The eggs hatch in the small intestine and the larva which emerges through the pole of the egg passes down into the caecum. In about 2 to 3 months they become mature adults and lie embedded on the caecal wall, with the thread-like anterior portion piercing the mucosa and the thick posterior end projecting out. Eggs start appearing in faeces usually about 3 months after infection.



**FIGURE:** Helminth eggs in human stools

The entire life cycle can be passed in one host, from the ingested infective egg to the development of the adults and the release of their eggs in faeces. But for transmission of infection to other hosts and perpetuation of the species, the egg has to undergo development in the soil and then infect another person. Humans are the only natural host for *T.trichiura*, but morphologically similar worms are found to infect pigs and some monkeys.





**FIGURE:** Life cycle of *Trichuris trichiura*. 1. Adult male and female in human caecum. 2 Freshly passed egg in faeces, containing unsegmented ovum. Not infective. 3. Mature egg in soil, containing coiled rhabditiform larva. Infective stage

### **Pathogenesis and Clinical Features**

Infection with *T.trichiura* (*trichuriasis*, *whipworm infection* or *trichocephaliasis*) is asymptomatic except when the worm load is heavy. Disease may result either due to mechanical effects or allergic reaction.

The worms lie threaded into the caecal mucosa and even though it is not a blood feeder, oozing of blood may occur at the sites of attachment. The blood loss is about 0.005 ml per worm per day. Over a period of time this may lead to anaemia and malnutrition.

It has been suggested that mechanical blockage of the appendiceal lumen by masses of whipworms may cause acute appendicitis. In heavy infection, the worm may be abundant on the colonic mucosa, even upto the rectum. Mucus diarrhoea, chronic dysentery and abdominal pain are frequently seen in such cases. Some patients, particularly young children may develop rectal prolapse.

### **Diagnosis**

The characteristic eggs are found in stools. The degree of infection can be assessed by egg counts. Less than 10 eggs per smear in direct stool preparation is considered light infection and more than 50 as heavy. Light infection is not considered to cause clinical disease. Proctoscopy is useful as worms are found on the rectal mucosa in whipworm diarrhoea and dysentery. Charcot-Leyden crystals are usually abundant in stools of patients with whipworm dysentery.

### **Treatment**

Mebendazole and albendazole are effective in treatment.

### **Prophylaxis**

Prevention of promiscuous defecation and proper disposal of feces would eliminate transmission of infection. Checking the consumption of unwashed fruits and vegetables grown on polluted fields can minimise the risk of infection.

## **ASCARIS LUMBRICOIDES**

### **History and Distribution**

The roundworm, *Ascaris lumbricoides* is the largest nematode parasite in the human intestine. It had been observed and described from very ancient times, when it was sometimes confused with the earthworm. Its specific name *lumbricoides* is derived from this resemblance (*Lumbricus*, meaning earthworm in Latin). It is the most common of human helminths and is distributed worldwide. A billion people are estimated to be infected with roundworms. The individual worm burden could be very high, even up to over a thousand. An editorial in the *Lancet* in 1989 observed that if all the roundworms in all the people worldwide were placed end-to-end they would encircle the world 50 times.

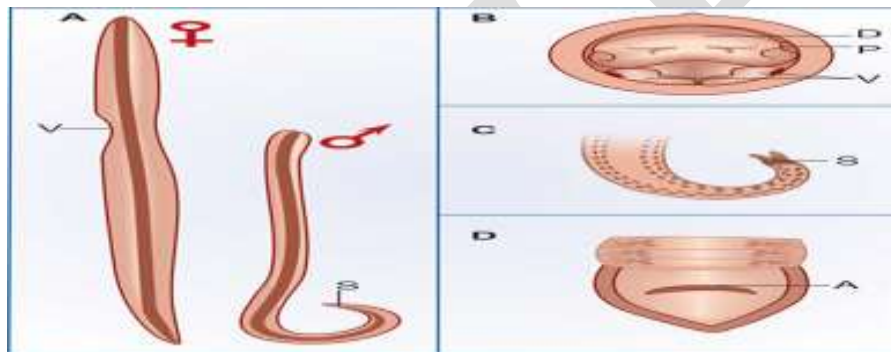
### **Morphology and Life Cycle**

The adult worms live in the small intestines of infected persons. They are large cylindrical worms, with tapering ends, the anterior end being more pointed than the posterior. They are pale pink or flesh coloured when freshly passed in stools, but become white outside the body. The mouth at the anterior end has three finely denticulated lips, one dorsal and two ventro-lateral.

The male measures 15 to 30 cm in length and 2 to 4 mm in thickness. Its posterior end is curved ventrally to form a hook and carries two copulatory spicules. The female is larger, 20 to 40 cm long and 3 to 6 mm thick. Its posterior extremity is straight and conical. The vulva is situated mid-ventrally, near the junction of the anterior and middle thirds of the body. A distinct groove is often seen surrounding the worm at the level of the vulvar opening. This is called the vulvar waist or genital girdle and is believed to facilitate mating.

The vulva leads to a single vagina, which branches into a pair of genital tubules that lie convoluted through much of the posterior two thirds of the body. The genital tubules of the gravid worm contain an enormous number of eggs as many as 27 million at a time. A single worm lays up to 200,000 eggs per day. The eggs are passed in faeces. Two types of eggs are passed by the worms. The fertilised eggs, laid by females inseminated by mating with a male, are embryonated and develop into the infective eggs. The uninseminated female also lays eggs, but these are non-embryonated and cannot become infective. These are called *unfertilised eggs*.

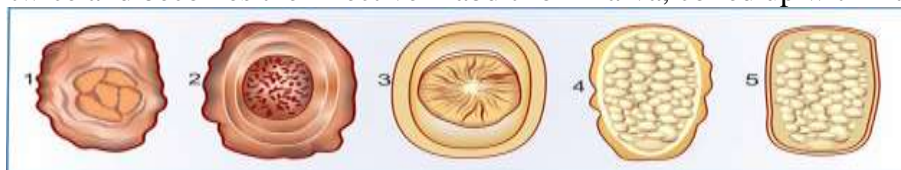The fertilised ascaris egg is spherical or ovoid, bile stained to a golden brown colour and measures 60 to 75  $\mu\text{m}$  in length and 40 to 50  $\mu\text{m}$  in breadth. It is enclosed in a stout translucent shell consisting of three layers, the outer coarsely mamillated albuminoid coat a thick transparent middle layer and the inner lipoidal vitelline membrane. Some eggs are found in feces without the outer mamillated coat. They are called the *decorticated eggs*. In the middle of the egg is a large unsegmented ovum, containing a mass of coarse lecithin granules. It nearly fills the egg, except for a clear crescentic area at either pole.



**FIGURE:** *Ascaris lumbricoides*. A. Adult male and female worms. Note the vulvar waist (v) in the female and the ventrally curved posterior end in the male with copulatory spicules(s). B. Anterior end of worm, head-on view, showing one dorsal (D) and two ventral. (V) lips, with papillae (P). C. Posterior end of male, showing two protruding copulatory spicules(s). D. Posterior end of female, showing anal opening (A) a little above the conical tip

The unfertilised egg is longer, up to 90  $\mu\text{m}$ , and more elliptical. The shell is thinner with the outer mamillary coat scanty and irregular. The ovum is atrophic and contains numerous disorganised, highly refractile granules of various sizes. The unfertilised egg is relatively heavy and does not float in saturated salt solution used for concentration by salt floatation while the fertilised eggs float. Stool samples may show both fertilised and unfertilised eggs, or either type alone.

The fertilised egg passed in feces, is not immediately infective. It has to undergo a period of incubation in soil before acquiring infectivity. The eggs are resistant to adverse conditions and can survive for several years. The development of the egg in soil depends on the nature of the soil and various environmental factors. A heavy clayey soil and moist shady location, with temperature between 20° and 30°C are optimal for rapid development of the embryo. The development usually takes from 10 to 40 days, during which time the embryo moults twice and becomes the infective rhabditiform larva, coiled up within the egg.



**FIGURE:** Types of ascaris eggs found in stools. 1. Fertilised egg surface focus. showing outer mamillary coat. 2. Fertilised egg. Median focus. Showing unsegmented ovum surrounded by three layers of coats. 3. Decorticated fertilised egg. The mamillary coat is absent. 4. Unfertilised egg. Elongated, with atrophic ovum. 5. Decorticated unfertilised egg

Infection occurs when the egg containing the infective rhabditiform larva is swallowed. A frequent mode of transmission is through fresh vegetables grown in fields manured with human feces ('night soil'). Infection may be transmitted through contaminated drinking water. Children playing about in mud can transmit eggs to their mouth through dirty fingers. Where soil contamination is heavy due to indiscriminate defecation, the eggs sometimes get airborne along with windswept dust and inhaled. The inhaled eggs get swallowed.

When the swallowed eggs reach the duodenum, the larvae hatch out. The rhabditiform larvae, about 250 µm in length and 14 µm in diameter, are actively motile. They penetrate the intestinal mucosa, enter the portal vessels and are carried to the liver. They then pass via the hepatic vein, inferior vena cava and the right heart, and in about four days reach the lungs, where they grow and moult twice. After development in the lungs, in about 10 to 15 days, the larvae pierce the lung capillaries and reach the alveoli. Then they crawl up or are carried up the respiratory passage to the throat and are swallowed. The larvae moult and develop into adults in the upper part of the small intestine. They become sexually mature in about 6 to 12 weeks and the gravid females start laying eggs. to repeat the cycle. The adult worm has a lifespan of 12 to 20 months.

#### **Pathogenesis and Clinical Features**

Clinical manifestations in ascariasis can be caused by either the migrating larvae or the adult worms. The pathogenic effects of larval migration are due to allergic reaction and not the presence of larvae as such. Therefore, the initial exposure to larvae is usually asymptomatic, except when the larval load is very heavy. But when reinfection occurs subsequently there may be intense cellular reaction to the migrating larvae in the lungs, with infiltration of eosinophils, macrophages and epithelioid cells. This ascaris pneumonia is characterised by low grade fever, dry cough, asthmatic wheezing, urticaria, eosinophilia and mottled lung infiltration in the chest radiograph. The sputum may contain Charcot-Leyden crystals. The larvae may occasionally be found in the sputum, but are seen more often in gastric washings. This condition is called *Loeffler's syndrome*. The clinical features generally clear in one or two weeks, though it may sometimes be severe and rarely even fatal. Loeffler's syndrome can also be caused by hypersensitivity to other agents, both living and non-living. Allergic inflammatory reaction to migrating larvae may involve other organs such as the kidney or liver. Very rarely the larvae may occlude a small vessel in the heart or brain.



**FIGURE:** Life cycle of *Ascaris lumbricoides*. 1. Adult worms in small intestine of man. 2. Egg passed in feces reaches soil. 3. Mature egg containing larva— infective for humans. 4. When swallowed, larva hatches out in duodenum. 5. Rhabditiform larva penetrates gut wall, circulates in blood stream, moults in lung, reaches pharynx and is swallowed to develop into the adult in intestine

Clinical manifestations due to adult worm vary from asymptomatic infection to severe and even fatal consequences. It is not unusual to find children apparently unaffected in spite of heavy infestation with the

worms. The pathological effects, when present, are caused by (i) Spoliative action, (ii) Toxic action, and (iii) Mechanical effects.

- i. The *spoliative* or *nutritional* effects are usually seen when the worm burden is heavy. The worms may be present in enormous numbers, sometimes exceeding 500, in small children, occupying a large part of the intestinal tract. This interferes with proper digestion and absorption of food. Ascariasis may contribute to protein-energy malnutrition and vitamin A deficiency. Patients have loss of appetite and are often listless. Abnormalities of the jejunal mucosa are often present, including broadening and shortening of villi, elongation of crypts and round cell infiltration of lamina propria. These changes are reversed when the worms are eliminated.
- ii. The so called *toxic* effects are due to hypersensitivity to the worm antigens and may be manifested as fever, urticaria, angioneurotic oedema, wheezing and conjunctivitis. These are more often seen in persons who come into contact with the worm occupationally, as in laboratory technicians and abattoir workers (who become sensitive to the pig ascarid *A. suum*), than in children having intestinal infestation.
- iii. The mechanical effects are the most important manifestations of ascariasis. Mechanical effects can be due to masses of worms causing luminal occlusion or even a single worm infiltrating into a vital area. The adult worms live in the upper part of the small intestine, where they maintain their position due to their body muscle tone, spanning the lumen. They may stimulate reflex peristalsis, causing recurrent and often severe colicky pain in the abdomen. The worms may be clumped together into a mass, filling the lumen, leading to volvulus, intussusception or intestinal obstruction.

The worms are restless wanderers apparently showing great inquisitiveness, in that they tend to probe and insinuate themselves into any aperture they find on the way. The wandering is enhanced when the host is ill, particularly when febrile, with temperature above 39°C. The male worm is more responsive to illness of the host, than the female. The worm may wander up or down along the gut. Going up, it may enter the opening of the biliary or pancreatic duct causing acute biliary obstruction or pancreatitis. It may enter the liver parenchyma, where it may lead to abscesses. The worm may go up the oesophagus and come out through the mouth or nose. It may crawl into the trachea and the lung causing respiratory obstruction or lung abscesses. Migrating downwards, the worm may cause obstructive appendicitis. It may lead to peritonitis when it perforates the intestine, generally at weak spots such as typhoid or tuberculous ulcers or through suture lines. This tendency makes preoperative deworming necessary before gastrointestinal surgery in endemic areas. The wandering worm may reach the kidneys, lungs or other organs and cause ectopic lesions.

### Diagnosis

In the early stages of infection, when migrating larvae cause Loeffler's syndrome, the diagnosis may be made by demonstrating the larvae in sputum, or more often in gastric washings. Presence of Charcot-Leyden crystals in sputum and an attendant eosinophilia support the diagnosis. At this stage no eggs are seen in feces.

The most important method for the diagnosis of ascariasis is the demonstration of eggs in feces. Ascarides are prolific egg layers. A single female may account for about 3 eggs per mg of feces. At this concentration, the eggs can be readily seen by microscopic examination of a saline emulsion of feces. Both fertilised and unfertilised eggs are usually present. Occasionally only one type is seen. The fertilised eggs may sometimes appear decorticated. Rarely, when the infestation is light, eggs are demonstrable only by concentration methods. The unfertilised eggs are not detectable by salt floatation. Eggs may not be seen if only male worms are present, as may occasionally be the case. Fecal films often contain many artefacts resembling



ascaris eggs and care must be taken to differentiate them. Sometimes the diagnosis becomes evident when the worm is passed either through the anus, or through the mouth or nose. A skin test with ascaris antigen gives a positive result, but is unreliable and not used for diagnosis. Serological tests are not useful in diagnosis. Diagnosis may often be made by barium contrast radiography of the abdomen.

### **Treatment**

Several safe and effective drugs are now available. These include pyrantel pamoate, albendazole, mebendazole and piperazine citrate.

### **Prevention**

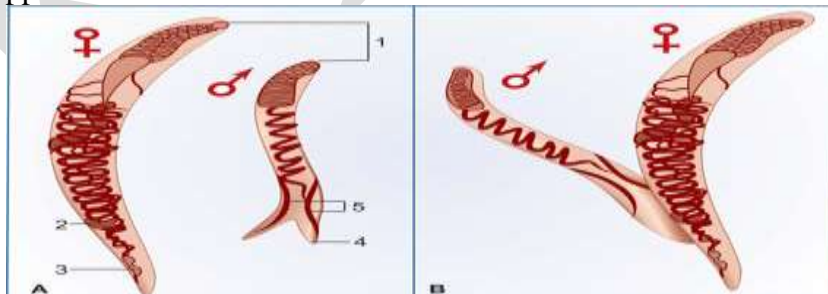
Ascariasis can be eliminated only if fecal contamination of soil can be prevented. The ascaris egg is highly resistant. Therefore the use of night soil as manure will lead to spread of the infection unless destruction of the eggs is ensured by proper composting. Treatment of vegetables and other garden crops with water containing iodine 200 ppm for 15 minutes kills the eggs and larvae of ascaris and other helminths.

## **ANCYLOSTOMA DUODENALE**

### **Morphology**

The adult worms live in the small intestines of infected persons, mostly in the jejunum, less often in the—duodenum and infrequently in the ileum. They are relatively stout cylindroidal worms. They are pale pink or greyish white, but may appear reddish brown due to ingested blood. The body is curved with the dorsal aspect concave and the ventral aspect convex. The anterior end is somewhat constricted and bent dorsally. This cervical curvature gave it the name hookworm. The mouth is not at the tip but directed dorsally. The prominent buccal capsule, reinforced with a hard chitin-like substance carries two pairs of hook-like teeth ventrally and a dental plate with a median cleft dorsally.

The male worm is about 8 to 11 mm in length and about 0.4 mm thick. The posterior end of the male is expanded into a copulatory bursa supported by fleshy rays. The pattern of the rays helps in distinguishing between different species. The cloaca into which the rectum and genital canal open is situated within the bursa. There are two long retractile bristle-like copulatory spicules, the tips of which project from the bursa. The female is larger, 10 to 13 mm long and 0.6 mm thick. Its hind end is conoid, with a subterminal anus situated ventrally. The vulva opens ventrally at the junction of the middle and posterior thirds of the body. The vagina leads to two intricately coiled ovarian tubes which occupy the hind and middle parts of the worm. During copulation the male attaches its copulatory bursa to the vulva. The copulating pair therefore presents a Y-shaped appearance.



**FIGURE:** (A) Morphology of *A. duodenale*. The body is curved, with dorsal surface concave and ventral surface convex. 1. Buccal capsule. 2. Vulva. 3. Anal pore. 4. Copulatory bursa. 5. Copulatory spicules (B) Male and female in copulation, forming a Y-shaped figure

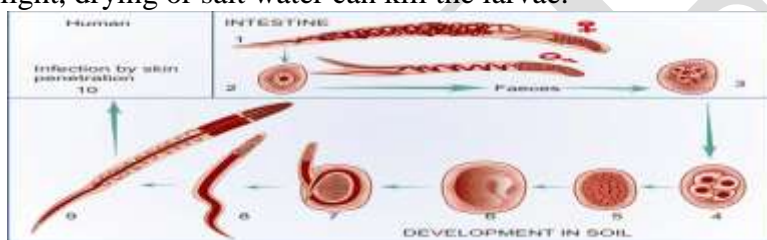The eggs are oval or elliptical, measuring 60  $\mu$ m by 40  $\mu$ m, colourless, not bile stained, with a thin transparent hyaline shell membrane. When released by the worm in the intestine, the egg contains an unsegmented ovum. During its passage down the intestine, the ovum develops. When passed in feces, the



egg contains a segmented ovum, usually with 4 or 8 blastomeres. There is a clear space between the segmented ovum and the egg shell. The eggs float in saturated salt solution. A single female worm lays about 25,000 to 30,000 eggs a day and some 18 to 54 million during its life time.

### Life Cycle

Humans are the only natural host. Eggs freshly passed in feces are not infective for humans. When deposited in the soil, the embryo develops inside the eggs. Its development takes place optimally in sandy loamy soil with decaying vegetation under a moist warm, shady environment. In about 2 days, a rhabditiform larva, about 250 µm long, hatches out of the egg. It feeds on bacteria and other organic matter in the soil, grows in size and moults twice, on the 3rd and 5th days after hatching, to become the third-stage infective filariform larva. It is about 500 to 600 µm long, with a sharp pointed tail. The filariform larvae are non-feeding. They can live in the soil for about 5 weeks, with their heads waving in the air, waiting for their hosts. They can also ascend on blades of grass or other vegetation, being carried in capillary water films on their surface. Direct sunlight, drying or salt water can kill the larvae.



**FIGURE:** Life cycle of *Ancylostoma duodenale*. 1. Adult male and female in human intestine. 2. Egg released by worm has an unsegmented ovum. 3. Egg passed in faeces has 4 to 8 blastomeres 4-7. Embryo undergoes development in soil. 8. Rhabditiform larva hatches out. 9. Filariform larva develops, which, 10. Infects humans by penetrating skin of feet. It circulates in blood, migrates through lungs on to pharynx and the intestine

When a person walks barefooted on soil containing the filariform larvae they penetrate the skin and enter the subcutaneous tissue. The common sites of entry are the skin between the toes, the dorsum of the foot and the medial aspect of the sole. In farm workers and miners the larvae may penetrate the skin of the hands. Rarely entry may be through skin on the other parts of the body. In the subcutaneous tissue the larvae enter the venules and are carried in circulation to the right heart and to the lungs. In the lungs, they break out of the capillaries to reach the alveoli, from where they migrate up the respiratory tract to the epiglottis. They crawl over the epiglottis to the pharynx and are swallowed. During migration or on reaching the jejunum, they moult and develop a temporary buccal capsule by which they get attached to the gut mucosa. They feed and grow in size, undergo a fourth and final moulting, develop the buccal capsule and grow into adults. There is no multiplication in the host and one infective larva develops into a single adult, male or female.

It takes usually about 6 weeks from the time of infection for the adult worms to become sexually mature and start laying eggs. But sometimes, there may be an arrest in development and the process may take much longer, 6 months or more. Rarely infection may take place by the oral route, the filariform larvae being carried on contaminated vegetables or fruits. The larvae may penetrate the buccal mucosa to reach the venous circulation and complete their migration via the lungs. Alternatively the larvae may be swallowed and may develop directly into adults in the small intestine without a tissue phase. Transmammary and transplacental transmission has been reported for *Ancylostome*, but not for *Necator*.

### Pathogenesis and Clinical Features

Clinical disease in hookworm infection may be due to larvae or adult worms. When the filariform larvae enter the skin, they cause severe local itching. An erythematous papular rash may develop, becoming vesicular. Scratching and secondary bacterial infection may follow. This condition, known as *ground itch*

occurs when large numbers of larvae penetrate the skin and is more common in infection with *Necator* than with *Ancylostome*. The condition is self-limited, lasting for 2-4 weeks.

The larvae may sometimes cause *creeping eruption (cutaneous larva migrans)*. This is more common in infections with animal hookworms than with human hookworms. The larvae migrate in tortuous tunnels between stratum germinativum and stratum corneum of the skin, causing serpiginous vesicular lesions. With advancing movement of the larvae, the rear portions of the lesions become dry and crusty. The lesion can be intensely pruritic. When larvae break out of the pulmonary capillaries and enter the alveoli, they may cause minute local hemorrhages. But clinical pneumonitis develops only in massive infections. The pulmonary syndrome, Loeffler's syndrome, commonly seen in ascariasis is rare in hookworm infection.

The more important manifestations of ancylostomiasis (hookworm disease) are caused by the adult worms in the intestine. The worms attach themselves to the gut mucosa by their buccal capsules. They suck into their mouth a portion of intestinal villi. They utilise gut epithelial cells and plasma for their food. Because of the pumping action of the oesophagus, the worm sucks in blood, which passes out undigested and unutilised through its intestines. An adult *Ancylostome* can suck about 0.2 ml blood a day, while the smaller *Necator* sucks in about 0.03 ml per day. The worms frequently leave one site and attach themselves to another site. As the secretions of the worm contain anticoagulant activity, bleeding from the site may continue for sometime. This adds to the blood loss. This chronic blood loss over a period of time leads to a microcytic hypochromic type of iron deficiency anaemia. The speed of onset of anaemia and its severity depend on the intensity of infection, body iron store and availability of dietary iron. The degree of anaemia is directly proportional to the worm burden. Worm loads of up to 100 worms are light and may cause no symptoms. Loads of 500 to 1000 or more cause significant blood loss and anaemia. The worm load is indicated by the egg count of feces. A count of less than 5 eggs per mg of faeces seldom causes clinical disease, while counts of 20 eggs or more are associated with significant anaemia. Egg counts of 50 or more represent massive infection. In hookworm disease, intestinal absorption of iron is apparently normal so that oral administration of iron can correct the anaemia. However, cure depends on elimination of the worms. Hookworm infection may cause an intestinal syndrome resembling peptic ulcer, with epigastric pain, dyspepsia and vomiting. There may be diarrhoea, the stool being reddish or black. This is more often seen in the acute stage, when the infection is heavy.

Hookworm anaemia leads to severe lassitude and dullness, affecting the working and learning capacities of patients. The haemoglobin level may drop drastically causing a characteristic sallow appearance of the skin—conjunctiva and tongue. Hypoproteinaemia develops, which is in excess of the red cell loss, and leads to protein—losing enteropathy, oedema and effusion in serous cavities. Severe hookworm anaemia commonly leads to cardiac failure. Patients present with exertional dyspnoea, palpitation, dizziness and generalised puffy oedema.

### **Diagnosis**

Demonstration of the eggs in faeces by direct microscopy or by concentration methods is the diagnostic test. In stool samples examined 24 hours or more after collection, the eggs may have hatched and rhabditiform larvae may be present. These have to be differentiated from strongyloides larvae. Egg counts give a measure of the intensity of infection. Adult hookworms may sometimes be seen in feces.

### **Treatment**

For specific anthelmintic treatment mebendazole and pyrantel pamoate are the drugs of choice. Thiabendazole is less effective. The old drug tetrachlorethylene is active, but toxic. Bephenium hydroxynaphthoate is active against *Ancylostoma* but not against *Necator*.

Treatment of hookworm disease includes relief of anaemia. Oral iron is effective, but in severe cases a preliminary packed cell transfusion may be needed. When the haemoglobin level is very low anthelmintic drugs should not be used before correcting the anaemia.

### **Epidemiology and Prevention**

The conditions required for maintenance of endemic hookworm infection are the presence of infected persons, dispersal of eggs in soil due to indiscriminate defecation and inadequate processing of excreta, appropriate environmental factors facilitating development of eggs in soil, and opportunity for the larvae to infect people through their exposed skin surfaces. These conditions prevail throughout the year in most parts of the tropics, but in subtropical areas, these conditions exist only seasonally, being limited to the warmer months.

Control depends on prevention of soil pollution with feces and proper disposal of night soil. The use of footwear prevents entry of larvae through the skin of the foot. Gloves give similar protection to the hands of farm workers. Treatment of patients and carriers, preferably all at the same time, limits the source of infection.

### **WUCHERERIA BANCROFTI**

#### **History**

Filariasis has been known from antiquity. Elephantiasis had been described in India by Sushruta (circa 600 BC) and in Persia by Rhazes and Avicenna. The term 'Malabar leg' was applied to the condition by Clarke in 1709 in Cochin. Microfilaria was first observed by Demarquay (1863) in the hydrocoele fluid of a patient from Havana, Cuba. The genus is named after Wucherer, a Brazilian physician who reported microfilariae in chylous urine in 1868. Microfilaria was first demonstrated in human blood in Calcutta by Lewis (1872), who called it *Filaria sanguinis hominis*. The female adult worm was described by Bancroft (1876) in Brisbane, Australia and the male worm by Bourne (1888). Manson (1878) in China identified the *Culex* mosquito as the vector. This was the first discovery of insect transmission of a human disease. Manson (1879) also demonstrated the nocturnal periodicity of microfilariae in peripheral blood.

#### **Distribution**

*W. bancrofti* is distributed widely in the tropics and subtropics of Asia, Africa and South America (Fig. 18.2). Over 900 million persons live in areas endemic for lymphatic filariasis and are therefore at risk of infection. In 1999, over 90 million persons were estimated to be infected, with or without clinical manifestations—over 81 million with *Wuchereria* and over 8 million with *Brugia*. The largest number of cases of filariasis occurs in India, where over 300 million people live in endemic zones. It is estimated that at least 6 million attacks of acute filarial disease occur every year in India and that over 15 million persons have chronic filarial disease. The endemic areas are mainly along the sea coast and along the banks of the large rivers, though infection occurs virtually in all states, except in the North West.

#### **Morphology and Life Cycle**

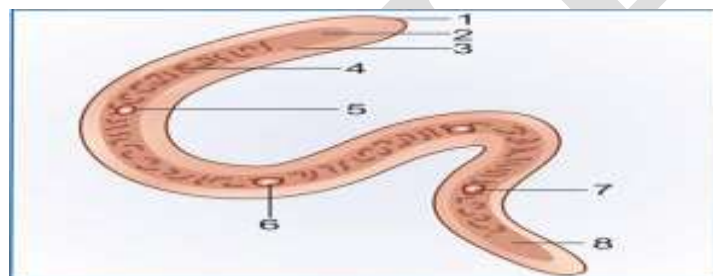
The adults are whitish, translucent, thread-like worms with smooth cuticle and tapering ends. The female is larger (70-100 × 0.25 mm) than the male (25-40 × 0.1 mm). Males and females remain coiled together usually in the abdominal and inguinal lymphatics and in the testicular tissues. The adult worms live for many years, probably 10 to 15 years or more.

The worm is ovoviviparous. The embryo (microfilaria) is released encased in its elongated egg-shell, which persists as a *sheath*. The microfilaria has a colourless translucent body with a *blunt head* and *pointed tail*. It measures 250 to 300 µm in length and 6 to 10 µm in thickness. It is actively motile and can move forwards and backwards within the sheath, which is much longer than the embryo.

When stained with Leishman or other Romanowsky stains, structural details can be made out. Along the central axis of the microfilaria can be seen a column of granules, which are called *somatic cells* or *nuclei*.

The granules are absent at certain specific locations—a feature which helps in the identification of the species. The specific locations are the following.

- At the head end is a clear space devoid of granules, called the *cephalic space*. In *Microfilaria bancrofti*, the cephalic space is as long as it is broad while in *M. malayi*, it is longer than its breadth. With vital stains a *stylet* can be demonstrated projecting from the cephalic space.
- In the anterior half of the microfilaria, is an oblique area devoid of granules called the *nerve ring*.
- Approximately midway along the length of the microfilaria is the *anterior V-spot* which represents the rudimentary excretory system.
- The *posterior V-spot* (Tail-spot) represents the cloaca or anal pore.
- The genital cells (G-cells) situated anterior to the anal pore.
- The internal (central) body of Manson extending from the anterior V-spot to G-cell 1, representing the rudimentary alimentary system.
- The tail tip, devoid of nuclei in *Mf. bancrofti*, bears two distinct nuclei in *Mf. malayi*



**FIGURE:** Morphology of *Microfilaria bancrofti*. 1. Sheath; 2. Stylet; 3. Cephalic space; 4. Nuclei; 5. Nerve ring; 6. Anterior V-spot; 7. Posterior V-spot; 8. Tail

The microfilariae circulate in the blood stream. In India, China and many other Asian countries. They show a nocturnal periodicity in peripheral circulation, being seen in large numbers in peripheral blood only at night, between 10 pm and 4 am. This correlates with the night biting habit of the vector mosquito. Periodicity may also be related to the sleeping habits of the hosts. It has been reported that if the sleeping habits of the hosts are reversed, over a period, the microfilariae change their periodicity from nocturnal to diurnal. Nocturnal periodic microfilariae are believed to spend the day time mainly in the capillaries of the lung and kidneys or in the heart and great vessels. In the Pacific islands and some parts of the Malaysian archipelago, the microfilariae are non-periodic or diurnal subperiodic, in that they occur in peripheral circulation at all times, with a slight peak during the late afternoon or evening. This is related to the day biting habits of the local vector mosquitoes. Humans are the definitive host. No animal host or reservoir is known for *W. bancrofti*. The intermediate host is the female mosquito, different species acting as vectors in different geographic areas. The major vector in India and most other parts of Asia is *Culex quinquefasciatus* (*C. fatigans*). Microfilariae do not multiply or undergo any further development in the human body. If they are not taken up by a female vector mosquito, they die. Their lifespan is believed to be about 2 to 3 months. It is estimated that a microfilarial density of at least 15 per drop of blood is necessary for infecting mosquitoes. Densities of 20,000 microfilariae or more per ml of blood may be seen in some carriers. When a vector mosquito feeds on a carrier, the microfilariae are taken in with the blood meal and reach the stomach of the mosquito. Within 2 to 6 hours, they cast off their sheaths (*exsheathing*), penetrate the stomach wall and within 4 to 17 hours migrate to the thoracic muscles where they undergo further development. During the next 2 days, they metamorphose into the first-stage larva which is a sausage-shaped form with a spiky tail, measuring  $125-250 \times 10-15 \mu\text{m}$ . Within a week, it moults once or twice,



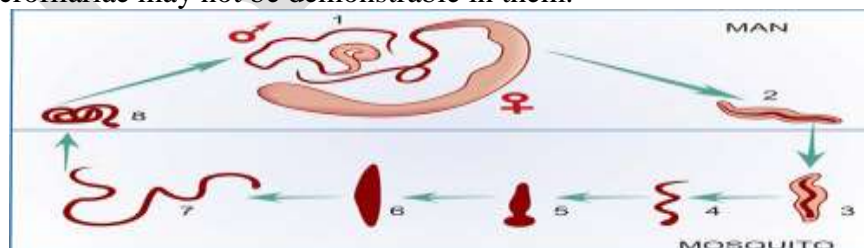
increases in size and becomes the second-stage larvae, measuring  $225-325 \times 15-30 \mu\text{m}$ . In another week, it develops its internal structures and becomes the elongated third-stage filariform larva, measuring  $1500-2000 \times 15-25 \mu\text{m}$ . It is actively motile. This is the infective larva. It enters the proboscis sheath of the mosquito, awaiting opportunity for infecting humans on whom the mosquito feeds. There is no multiplication of the microfilaria in the mosquito and one microfilaria develops into one infective larva only. The time taken from the entry of the microfilaria into the mosquito till the development of the infective third-stage larva located in its proboscis sheath, constitutes the *extrinsic incubation period*. Its duration varies with environmental factors such as temperature and humidity as well as with the vector species. Under optimal conditions, its duration is 10 to 20 days.

When a mosquito with infective larvae in its proboscis feeds on a person, the larvae get deposited, usually in pairs, on the skin near the puncture site. The larvae enter through the puncture wound or penetrate the skin by themselves. The infective dose for man is not known, but many larvae fail to penetrate the skin by themselves and many more are destroyed in the tissues by immunological and other defence mechanisms. A very large number of infected mosquito bites are required to ensure transmission to man, perhaps as many as 15,000 infective bites per person. After penetrating the skin, the third-stage larvae enter the lymphatic vessels and are carried usually to abdominal or inguinal lymph nodes, where they develop into adult forms. There is no multiplication at this stage and only one adult develops from one larva male or female. They become sexually mature in about 6 months and mate. The gravid female worm releases large numbers of microfilariae, as many as 50,000 per day. They pass through the thoracic duct and pulmonary capillaries to the peripheral circulation.

The period from the entry of the infective third-stage larvae into the human host till the first appearance of microfilariae in circulation is called the biological incubation period or the prepatent period. This is usually about 8 to 12 months. The period from the entry of the infective larvae, till the development of the earliest clinical manifestation is called the clinical incubation period. This is very variable, but is usually 8 to 16 months, though it may often be very much longer.

### Pathogenesis

The outcome of filarial infection varies in different persons. In endemic areas, infection may be entirely asymptomatic in most persons. Carriers may have very high microfilarial density in peripheral blood (20,000 per ml or more) without any ill effects. Such persons appear to tolerate microfilariae, the immune response being inhibited by antigen-specific suppressor cells or other suppressor factors. On the other hand, in persons coming to endemic areas from places where filariasis is absent, infection may cause early clinical manifestations such as lymphangitis and lymphadenitis. They mount an immune response against the infection, so that microfilariae may not be demonstrable in them.



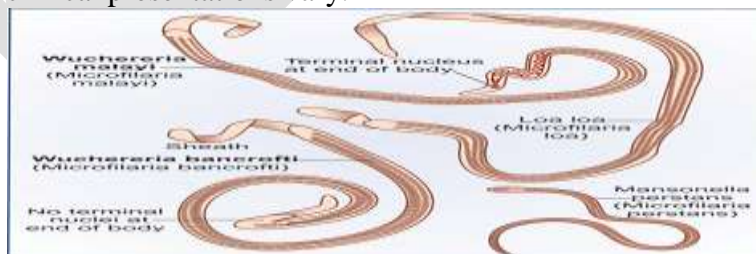
**FIGURE:** Life cycle of *W. bancrofti*. 1. Adult male and female in lymph node; 2. Microfilaria in peripheral capillaries at night. 3. Microfilaria ingested by mosquito reaches its stomach where it; 4. Sheds its sheath, penetrates gut wall and enters thoracic muscles where it develops into; 5. Short first-stage larva; 6. Second-stage larva and; 7. Infective third-stage larva which lies in the proboscis sheath. When the mosquito bites a person, it is deposited on the skin; 8. Penetrates, reaches lymphatics and develops into adult



The infective larvae that enter the human body through mosquito bite migrate in the lymphatics and moult, during which they release their body proteins, secretions and other products. In some persons these may cause irritation, directly or due to hypersensitivity or other immunological inflammation. Immune reactions are more common when the worms become adults. The typical manifestations of filariasis are caused by the adult worms blocking lymph nodes and vessels, either mechanically or more commonly due to allergic inflammatory reactions to worm antigens and secretions. The affected lymph nodes and vessels are infiltrated with macrophages, eosinophils, lymphocytes and plasma cells, and show endothelial hyperplasia. The vessel walls get thickened and the lumen narrowed or occluded, leading to lymph stasis and dilatation of lymph vessels. The worms inside lymph nodes and vessels may cause granuloma formation, with subsequent scarring and even calcification. Inflammatory changes damage the valves in lymph vessels, further aggravating lymph stasis. Increased permeability of lymph vessel walls leads to leakage of protein-rich lymph into the tissues. This produces the typical hard pitting or brawny oedema of filariasis. Fibroblasts invade the oedematous tissues, laying down fibrous tissue, producing the non-pitting gross oedema of Animal models have been developed, such as experimental filarial infection in cats with *Brugia pahangi* or *Br. malayi*. These have helped in understanding the pathogenesis of the disease, but in cats and other animals, filarial infection does not cause elephantiasis. Elephantiasis is a feature unique to human filariasis, apparently caused by human erect posture and consequent hydrodynamic factors affecting lymph flow. In some persons, immune reactions to filarial antigens may produce clinical conditions unrelated to the lymphatic lesions described above. In these, microfilariae are not demonstrable in blood. These are known as *occult filariasis*.

### **Clinical Manifestations**

Filariasis leads to a wide spectrum of clinical manifestations, ranging from carrier state with no evident disease to chronic incapacitating illness. Filariasis does not kill, but may cause great suffering, disfiguration and disability. The earliest manifestations are seen during the stage of 'invasion', when the infective larvae enter the body and undergo development. In some persons, hypersensitivity to the antigens of the larvae causes constitutional symptoms such as malaise, headache, nausea, vomiting and low grade fever. Recurrent attacks of pruritus and urticaria may occur. Some develop 'fugitive swellings'—raised, painless, tender, diffuse, red areas on the skin, commonly seen on the limbs. These disappear spontaneously after a few days, but may reappear at the same or different sites. The characteristic manifestations of filariasis are due to obstruction of lymph vessels and nodes. The essential features are lymphadenopathy, lymphangitis, lymphangiovarix, lymphorrhagia or chylorrhagia, hydrocoele, lymphoedema and elephantiasis. Depending on the sites affected, the clinical presentations vary.



**FIGURE:** Microfilaria from human blood. Thick drop, haematoxylin staining Magn. x 700

### **Lymphadenitis**

Repeated episodes of acute lymphadenitis with fever occur very frequently. The inguinal nodes are most often affected and axillary nodes less commonly. The swollen nodes may be painful and tender.

### ***Lymphangitis***

The acutely inflamed lymph vessels may be seen as red streaks underneath the skin. Lymphatics of the testes and spermatic cord are frequently involved, with epididymo-orchitis and funiculitis. Acute lymphangitis is usually caused by allergic or inflammatory reaction to filarial infection, but may often be associated with streptococcal infection also.

### ***Filarial Fever***

High fever of sudden onset, often with rigor, lasting for two or three days is the typical picture. This occurs repeatedly at intervals of weeks or months. It is accompanied by lymphangitis and lymphadenitis, with resultant lymphoedema. When the lymph nodes affected are intra-abdominal and hence not noticeable, the diagnosis may be difficult.

### ***Lymphangiovarix***

Dilatation of lymph vessels commonly occur in the inguinal, scrotal, testicular and abdominal sites.

### ***Lymphorrhagia***

Rupture of lymph varices leads to the release of lymph or chyle. The clinical picture depends on the sites involved and include lymph scrotum, lymphocele, chyluria, chylous diarrhoea, chylous ascites and chylothorax.

### ***Hydrocoele***

This is a very common manifestation of filariasis. Accumulation of fluid occurs due to obstruction of lymph vessels of the spermatic cord and also by exudation from the inflamed testes and epididymis. The fluid is usually clear and straw coloured, but may sometimes be cloudy, milky or haemorrhagic. The hydrocoele may be unilateral or bilateral and is generally small in size in the early stage, but may occasionally assume enormous proportions in association with elephantiasis of the scrotum. The largest reported hydrocoele weighed over 100 kilograms.

### ***Lymphoedema***

This follows successive attacks of lymphangitis and usually starts as swelling around the ankle, spreading to the back of the foot and leg. It may also affect the arms, breast, scrotum, vulva or any other part of the body. Initially the oedema is pitting in nature, but in course of time becomes hard and nonpitting.

### ***Elephantiasis***

This is a delayed sequel to repeated lymphangitis, obstruction and lymphoedema. Lymph exudate accumulating in the region stimulates connective tissue hypertrophy and hyperplasia. The part gets grossly enlarged and misshapen. The skin surface becomes coarse, with warty excrescences. Cracks and fissures develop with secondary bacterial infection. Elephantiasis is seen most commonly in the leg, but may also involve other parts of the body including the arm, breast, scrotum, penis and vulva.

### ***Occult Filariasis***

This term is applied to clinical conditions not directly due to lymphatic involvement, but to hypersensitivity reactions to filarial antigens. Here microfilariae are not seen in blood but may be present at the affected sites. The condition may be caused by *Wuchereria*, *Brugia* or by some animal filaria also.

The best studied syndrome of occult filariasis is *Tropical Pulmonary Eosinophilia*, which presents with low grade fever, loss of weight, anorexia and pulmonary symptoms such as dry nocturnal cough, dyspnoea and asthmatic wheezing. Blood eosinophil count is above 3000 per cmm and may even go up to 50,000 or more. IgG levels are elevated. Chest radiography shows mottled shadows resembling military tuberculosis. Young adults are more commonly affected. There is considerable geographical difference in its incidence, which is probably genetically conditioned. Microfilariae are not usually detectable in blood, but lung biopsies have shown microfilariae in some cases. It has been suggested that in these cases, there is a failure

in the suppression of immune response to microfilarial antigens, so that microfilariae are filtered out and destroyed in the lungs, with allergic inflammatory reaction. Serological tests with filarial antigens are usually strongly positive. Nonspecific antibody production occurs and biological false-positive reactions are often seen in serological tests for syphilis. Prompt response to DEC confirms the diagnosis. Occult filariasis has also been reported to cause arthritis, glomerulonephritis, thrombophlebitis, tenosynovitis and dermatoses. Endomyocardial fibrosis has been claimed to be associated with filariasis, but the relationship has not been proven.

### **Diagnosis**

The diagnosis of filariasis depends on the clinical features, history of exposure in endemic areas and on laboratory findings. The laboratory tests that can be used for diagnosis include the following:

- a) Demonstration of microfilaria in peripheral blood. Microfilaria may also be detected in other specimens such as chylous urine or hydrocoele fluid. Sometimes it can be seen in biopsy specimens.
- b) Demonstration of the adult worm in biopsy specimens.
- c) Skin tests with filarial antigens.
- d) Demonstration of antibody to filarial antigens by serological tests.
- e) Demonstration of filarial antigens in blood by serological tests.
- f) Indirect evidence such as eosinophilia.

Demonstration of microfilaria in the peripheral blood is the diagnostic test most commonly employed. It is also the method used for carrier surveys. It has also the advantage that the species of the infecting filaria can be identified from the morphology of the microfilaria seen. In India and other areas where the prevalent filarial species is nocturnal periodic, 'night blood' samples are collected between 10 pm and 4 am. Microfilaria can be demonstrated in unstained as well as stained preparations.

### **Unstained Film**

From a finger prick, two or three drops of blood are collected on a clean glass slide, a cover slip applied and sealed with vaseline. Examination under the low power microscope will show the actively motile microfilariae lashing the blood cells around. The examination may be conveniently made the next morning as microfilariae retain their viability and motility for a day or two at room temperature.

### **Stained Film**

A 'thick and thin' blood smear is prepared on a clean glass slide and dried. The thick part of the smear is dehaemoglobinised by applying distilled water. The smear is fixed in methanol and stained with Giemsa, Leishman or polychrome methylene blue stains. Microfilariae may be seen under the low power microscope in the thick film. Their morphology can be studied in the thin film. By using a micropipette for taking a known quantity of blood (20 to 60 cu mm) for preparing the smear and counting the number of microfilariae in the entire stained smear, microfilaria counts can be obtained.

### **Concentration Techniques**

When the microfilaria density is low, examination of large volumes of blood, 1 ml or more, gives more positive results. Concentration techniques are used for this purpose. In the *sedimentation* methods, blood is obtained by venepuncture, the red cells lysed and the microfilariae concentrated by centrifugation. In the *filtration* methods used at present larger volumes of blood, up to 5 ml can be filtered through Millipore or nucleopore membranes. The membranes may be examined as such or after staining, for microfilariae. The filter membrane technique is much more sensitive so that blood can be collected even during day time for screening. The disadvantages of the technique are the cost and the need for venepuncture.

### **DEC Provocation Test**

A small dose of diethyl carbamazine (2 mg per kg body weight) induces microfilariae to appear in peripheral blood even during day time. For surveys, blood samples can be collected 20 to 50 minutes after

the administration of one 100 mg tablet of DEC to adults. Microfilaria may be demonstrated in centrifuged deposits of lymph, chylous urine or other appropriate specimens. Adult filarial worms can be seen in sections of biopsied lymph nodes, but this is not employed in routine diagnosis. Intradermal injection of filarial antigens (extracts of microfilariae, adult worms and third-stage larvae of *Br.malayi* or of the dog filaria *Dirofilaria immitis* induces an immediate hypersensitivity reaction. But the diagnostic value of the skin test is very limited due to the high rate of false-positive and negative reactions. Several serological tests, including complement fixation, indirect haemagglutination, indirect fluorescent antibody, immunodiffusion and immunoenzyme tests have been described. But the tests available now are not sufficiently sensitive or specific to be used either for individual diagnosis or surveys. Highly sensitive techniques are now being tried for detection of filarial antigens in blood.

### **Prevention and Control**

The two major measures in prevention and control of filariasis are eradication of the vector mosquito and detection and treatment of carriers. The recommended treatment is diethyl carbamazine (DEC) 6 mg per kg body weight daily for 12 days, the drug being given for 2 weeks, 6 days in a week. The treatment may have to be repeated in endemic areas, every 2 years or so. Mass chemotherapy has been tried, but it may pose difficulties in large endemic areas such as India. As DEC is non-toxic, it can be safely administered in combination with food items such as common salt.

### **Treatment**

DEC is the drug of choice. It is actively microfilaricidal, and in large enough doses may be fatal to adult worms also. Allergic reactions may occur due to the release of antigens from the large numbers of microfilariae which die on administration of the drug.

### Possible Questions

#### Part B (Two marks)

1. Define Helminthic infection.
2. Define Nematodes.
3. What is blood fluke?
4. Write few points about the morphology of *Taenia solium*?
5. What is meant by Trematode?

#### Part B (Eight marks)

1. Explain the morphology and lifecycle of *Tenia solium* with a neat diagram.
2. Illustrate and explain the morphology and life cycle of *Schistosoma hematobium*.
3. Write a short note on *Schistosoma*?
4. Explain the life cycle of *Schistosoma hemtobium* with a neat diagram?
5. Illustrate and Explain the morphology and life cycle of *Trichuris trichura*.
6. Explain the lifecycle of *Trichuris trichura*.
7. Illustrate and Explain the morphology of *Ascaris lumbricoides*?
8. Expalin the lifecycle of *Ascaris lumbricoides* with neatd diagram.
9. Write few points about the morphology of *Ascaris lumbricoides*?
10. Write few points about the morphology of *Wuchereria bancrofti*?
11. Explain the morphology and lifecycle of *Wuchereria bancrofti* with a neat diagram.
12. Explain the life cycle of *Wuchereria bancrofti*.
13. Illustrate and explain the morphology of *Wuchereria bancrofti*.
14. Explain the morphology and lifecycle of *Ancylostoma duodenale* with a neat diagram.



	Unit V	Option 1	Option 2	Option 3	Option 4	Answer
1	"Flask-shaped" intestinal ulcers are produced in infection with	Entamoeba. histolytica	Giardia lamblia	Ent. Polecki	Balantidium coli	Entamoeba. histolytica
2	The eggs of which of the following schistosoma sps. Are elongate and have a prominent lateral spine	S.mansoni	S.japonicum	S.haematobium	S.intercalatum	S.mansoni
3	Which of the following parasitic infection is not common in India	Amoebiasis	Kala-azar	Schistosomiasis	Whipworm infection	Schistosomiasis
4	The drug of choice for treatment of acute Chagas' disease is	Lampit	Metronidazole	Praziquantel	Corticosteroids	Lampit
5	Anisakiasis is usually caused by	Third stage larva	Adult stage of the worm	Ingestion of raw fish containing eggs	After one more febrile attack	Third stage larva
6	Which of the following is not a correct statement regarding Schistosomes	Adult worms live in veins and venules	Snails are intermediate hosts	There is no effective treatment	Eggs are not operculated	There is no effective treatment
7	Which of the following is true about trematodes	Hermaphrodite with the exception	It has been classified as a fungus	Lymphadenopathy is common in aute stage	Prophylatic treatment is indicated in AIDS patien	Hermaphrodite with the exception
8	Which of the following is not a cestode	Diphyllobothrium	Hymenolepsis	Schistosoma	Taenia	Schistosoma
9	All the following parasitic infections are acquired by ingestion of infective eggs except :	Ascaris lumbricoides	Enterobius vermicularis	Ancylostoma duodenale	Trichuris trichuria	Ancylostoma duodenale
10	L-D bodies in Kala-azar diagnosis represent	Promastigotes	Amastigotes	Modified eosinopois	Macrophages	Amastigotes
11	Very high eosinophilia is associated with which of the following	Trichinosis	Enterobiasis	Hydatid migrans	Ascariasis	Trichinosis
12	Eosinophils kill the	Production of	Intracellular	Extracellular killing	Activation of	Extracellular

	parasites by	antibodies	digestion		monocellular cell	killing
13	Which of the following species of schitosome can lodge in the veins of urinary bladder and cause haematuria	Schistosoma mansoni	Schistosoma haematobium	Schistosoma japonicum	Wucheria bancrofti	Schistosoma haematobium
14	Praziquantal is an effective treatment of infections with	Schistosoma mansoni	Schistosoma mansoni + Schistosoma japonicum	Schistosoma insomia	Schistosoma japonicum + Schistosoma haematobium	Schistosoma japonicum + Schistosoma haematobium
15	Which of the following has been associated with Schistosomiasis	Carcinoma of the urinary bladder	Carcinoma of liver	Carcinoma of small intestine	Carcinoma of	Carcinoma of lung
16	All the following parasites can be encountered in the lungs except	Pneumocystis carinii	Echinococcus sps	Paragonimus westermani	Taenia solium	Taenia solium
17	'Normal life span of strongyloides stercoralis is around	2 years	5 years	12 years	30 years	30 years
18	All the following nematodal infections occur by ingestion of infective eggs except	Ascaris lumbricoides	Strongloides streccoralis	Enterobius vermicularis	Trichuris trichuria	Strongloides streccoralis
19	Which of the following adult worms are found in lymphatics and lymph nodes	Wucheria bancrofti	Loa loa	Guinea worm	Roundworm	Wucheria bancrofti
20	Charcot Leyden crystals are derivatives of	Polymorphs	Eosinophils	Macrophages	Basophils	Eosinophils
21	Wuchereria is an example for .....	Flagellates	Ameobas	Round Worms	Tape Worms	Round Worms
22	Schistosoma comes under class .....	Nematoda	Cestoda	Trematoda	Aschelminthes	Trematoda
23	Entamoeba is included in subphylum .....	Mastigophora	Sarcodina	Ciliophora	Apicomplexa	Sarcodina

24	.....Of Schistosoma is responsible for Schistosomiasis.	Ova	Cyst	Schizonts	trophozoites	Ova
25	Which of the following can infect the central nervous system	Taenia solium	Trichomonas vaginalis	Entamoeba histolytica	Giardia lamblia	Taenia solium
26	Human beings are primarily infected with .....	Nematodes	Hookworm	Fluke	Helminth	Nematodes
27	Common name for phylum Apicomplexa is .....	Sporozoans	Ciliates	Flagellates	Ameobas	Sporozoans
28	Helminths consists of ...	Single Cell	Row of Cells	Multiple Cells	Double cells	Multiple Cells
29	The common name for parasites of class Nematode is .....	Tape Worms	Round Worms	Ring Worms	Flukes	Round Worms
30	Fluke is the common name for .....	Nematoda	Cestoda	Trematoda	Aschelminthes	Trematoda
31	Paragonimiasis is most likely associated with:	Dysentery	Haemoptysis	Jaundice	Haematuria	Haemoptysis
32	The only protozoan consistently associated with eosinophils is:	Isospora belli	Entamoeba histolytica	Dientamoeba fragilis	Trichomonas vaginalis	Isospora belli
33	Which of the following infection is not associated with eosinophilia	Trichinosis	Onchocerciasis	Hydatid disease	Ascariasis	Trichinosis
34	Granulomatous amoebic encephalitis is caused by	Entamoeba histolytica	Acanthamoeba	Naegleria	Dientamoeba fragilis	Acanthamoeba
35	PAM ( Primary amoebic meningoence phalitis) is caused by	Entamoeba histolytica	Naegleria fowleri	Balantidium coli	Giardia lamblia	Naegleria fowleri
36	Large cystic structures develop in the liver, when humans ingest the eggs of	Echinococcus granulosus	Taenia solium	Diphyllobothrium latum	Hymenolepis nana	Echinococcus granulosus
37	Cutaneous larva migrans is	Dog hookworms	Whipworm	Human hookworm	Pinworms	Dog hookworms

	caused by					
38	Definite diagnosis may be made by muscle biopsy in infection with	Trichinella spiralis	Hookworm	Whipworm	Thread worm	Trichinella spiralis
39	The adult worm of <i>Clonorchis sinensis</i> is most frequently found in	Intrahepatic bile duct	Lung parenchyma	Urinary bladder submucosa	Lumen of Intestine	Intrahepatic bile duct
40	The infection of fasciolopsiasis is acquired by	Ingestion of raw aquatic vegetation	Ingestion of raw fresh water fish	Ingestion of raw fresh water plant	Ingestion of raw fresh water snails	Ingestion of raw aquatic vegetation
41	Which of the following can infect the central nervous system -----	Taenia solium	Toxoplasma gondii	Echinococcus sps	Ascaris	Echinococcus sps
42	All the following drugs paralyse the worms except	Plasmodium	Isospora	Balantidium	Toxoplasma	Balantidium
43	Humans serve as definite hosts for all the following except	Taenia saginata	Taenia solium	Diphyllobothrium latum	Echinococcus granulosus	Echinococcus granulosus
44	Humans are both intermediate and definitive hosts for	Taenia solium	Taenia saginata	Hymenolepis nana	Echinococcus multilocularis	Hymenolepis nana
45	Humans acquire infection by eating raw or undercooked fish infected with	Taenia solium	Hymenolepis nana	Diphyllobothrium latum	Echinococcus granulosus	Diphyllobothrium latum
46	Which of the following parasite is well known for undergoing antigenic variation very frequently	Schistosoma mansoni	Trypanosoma brucei	Plasmodium vivax	Ascaris lumbricoides	Trypanosoma brucei
47	The relapses in African trypanosomiasis are due to	New variable antigenic types	Hypnozoite formation	Activation of suppressor T cells	Activation of suppressor B cells	New variable antigenic types
48	Clabar swellings are seen in patients who are infected with	Loa loa	Dracunculus medinensis	Wuchereria bancrofti	Onchocerca volvulus	Loa loa
49	Which of the following is	Trichinella	Leishmania sps	Toxoplasma gondii	Cryptosporidium	Trichinella

	best diagnosed by muscle biopsy	spiralis			parvum	spiralis
50	All the following parastic infections can be found in lungs except	Microsporidia	Toxoplasma gondii	Cryptosporidium parvum	Acanthamoeba	Acanthamoeba
51	The natural habitat for Balantidium coli is in the large intestine of	Pigs	Monkeys	rat	cat	Pigs
52	The approximate size of the trophozoite of Balantidium coli is	16-22mm x 4-6mm	40-60mm x 20x30mm	60-80mm x 40-70mm	50-200mm x 40-70mm	50-200mm x 40-70mm
53	The eggs of Paragonium westermani are usually confused with	Diphyllobothrium latum	Threadworm	Hookworm	Whipworm	Diphyllobothrium latum
54	All the following allergic reactions responsible for disease in parasitic infections are type IV except	Nephrotic syndrome in malaria	Elephantiasis	Spectral disease	Katayama fever	Nephrotic syndrome in malaria
55	All the following parasites evade the host immune response by surviving in macrophages except	Toxoplasma gondii	Trypanosoma cruzi	Leishmania sps	Trichinella spiralis	Trichinella spiralis
56	The parasitic disease recently eradicated from India is	Filariasis	Guinea worm	Balantidiasis	Kala-azar	Guinea worm
57	The guinea worm infection is acquired by	Mosquito bite	Sandfly bite	Ingestion of infected Cyclops	Inhalation of eggs	Ingestion of infected Cyclops
58	Enuresis is usually associated with infection of	Ascaris lumbricoides	Trichinella spiralis	Enterobius vermicularis	Entamoeba histolytica	Enterobius vermicularis
59	Threadworm infections are mostly found in	Upper classes	Normal	Almost always elevated	Below normal	Upper classes
60	If left untreated kala-azar is	self limiting disease	20-40% f	75-100%	Occasionally fatal	75-100%





## **KARPAGAM ACADEMY OF HIGHER EDUCATION**

**CLASS: II M.Sc MB**

**COURSE CODE: 18MBP303**

**COURSE NAME: MEDICAL MYCOLOGY AND PARASITOLOGY**

**UNIT: V**

**BATCH-2087-2020**

**KARPEE**